Infective agents

Dr Phil Bryant, Wales, UK

Infective agents

- Recognise causative agents valuable in diagnosis
- Many agents involved in infective processes:
  1. Bacteria
  2. Protozoa
  3. Helminths
  4. Fungi
  5. Viruses
- Identification made by appearance and staining:
  - H&E
  - Special stains
  - Fluorescent methods
  - Immunochemistry
- Histology should be supported by microbiology

1

BACTERIA

Bacteria

- Morphologically, bacteria are classified into:

  cocci 

  bacilli 

- Gram stain classifies bacteria into Gram-positive and Gram-negative
- Hans Christian Gram (1882), Danish microbiologist

GRAM STAIN

Bacterial cell wall structure

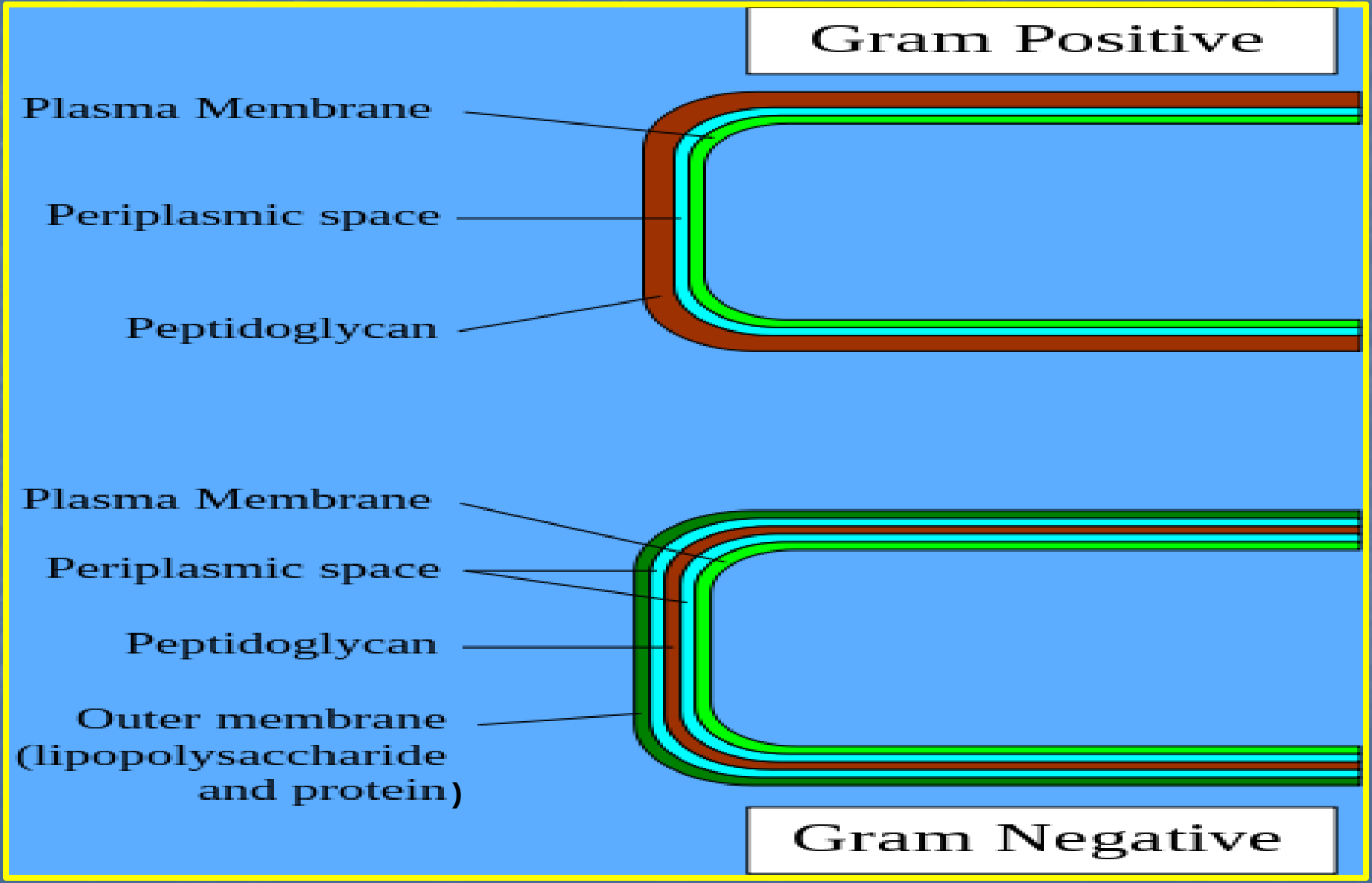

Gram positive bacteria

- High peptidoglycan and low lipid content in cell walls
- Cell walls are stained with crystal violet
- Iodine (mordant) penetrates and alters the crystal violet so the dye complex cannot be removed easily during decolourization (fixing the dye)
- Solvent (alcohol, acid alcohol) also closes pores as cell wall shrinks during dehydration
- Gram positive bacteria retain crystal violet / iodine complex

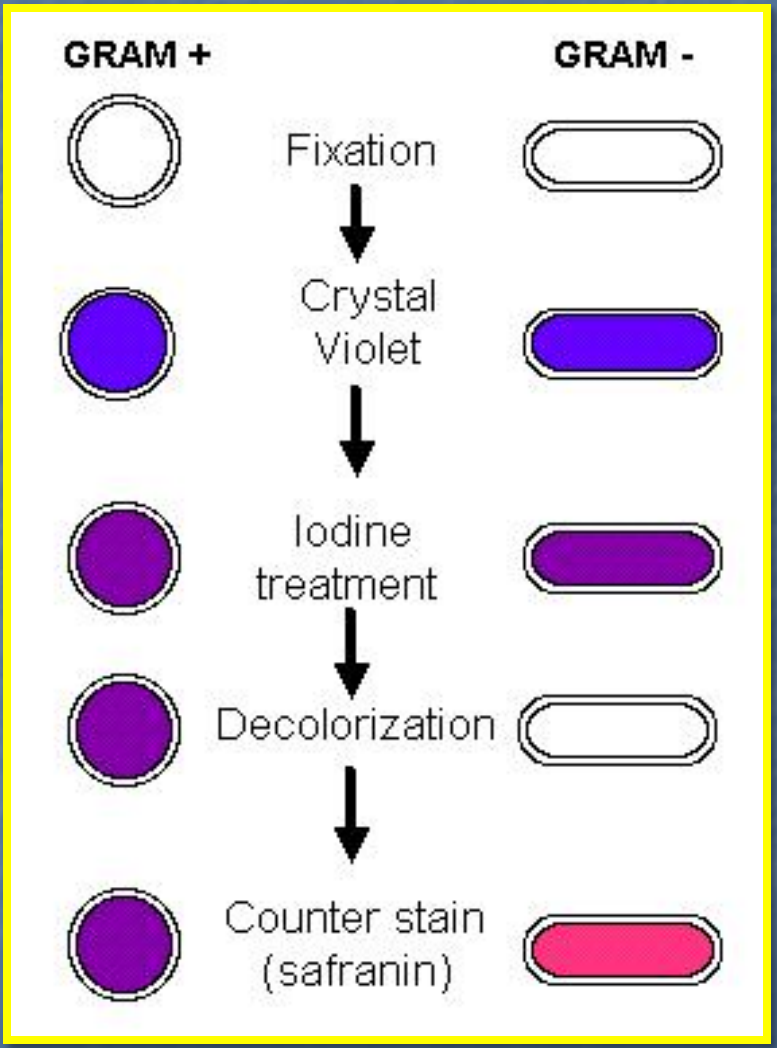

Gram negative bacteria

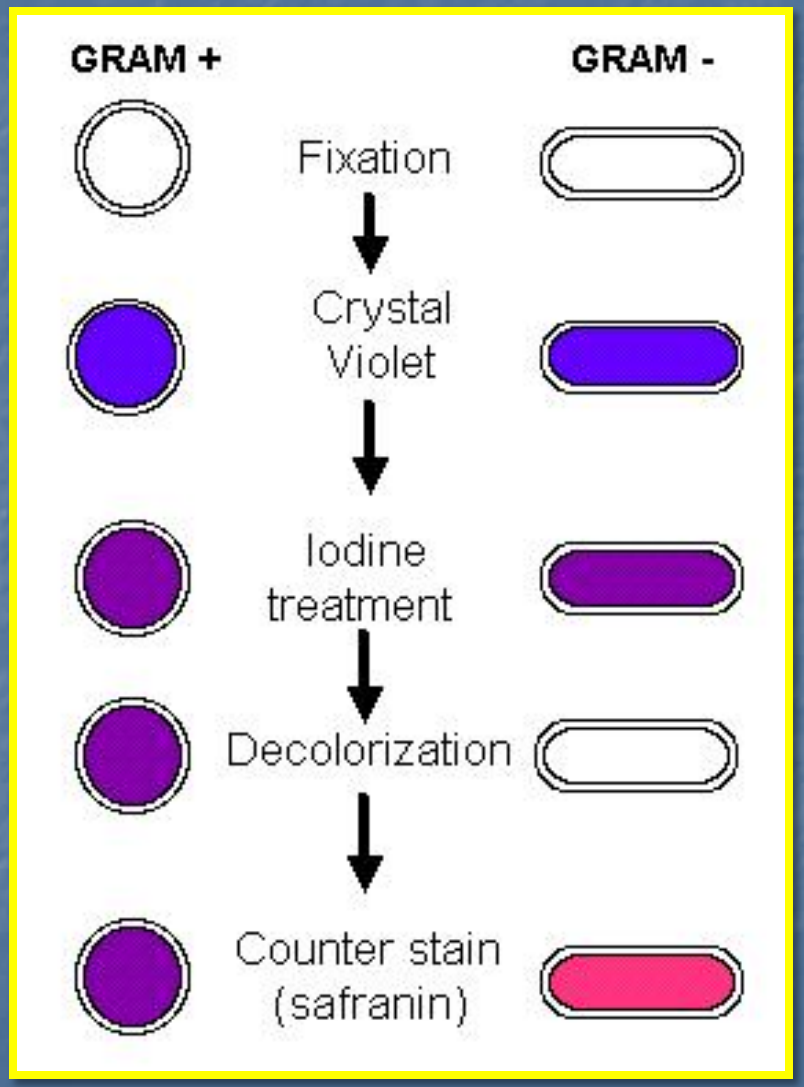

- Cell wall composed of lipopolysaccharides
- These groups are soluble in the decolourizer
- Gram negative bacteria lose the crystal violet / iodine colour
- Gram negative bacteria stain red with safranin (or neutral red) counterstain
- Stains more intensely if basic fuchsin is used (Brown and Brenn method)

Gram stain morphology

Gram positive cocci in clusters: Staphylococci



Gram positive cocci in chains: Streptococci

Gram positive bacilli:



Gram negative cocci:



Gram negative bacilli :

Gram stain results

Gram positive bacteria

Gram negative bacteria

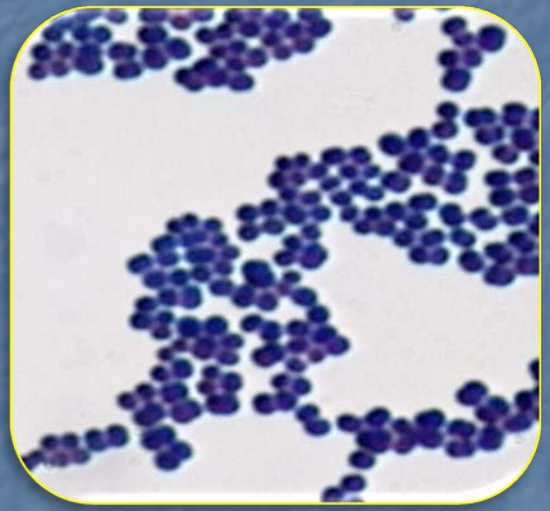

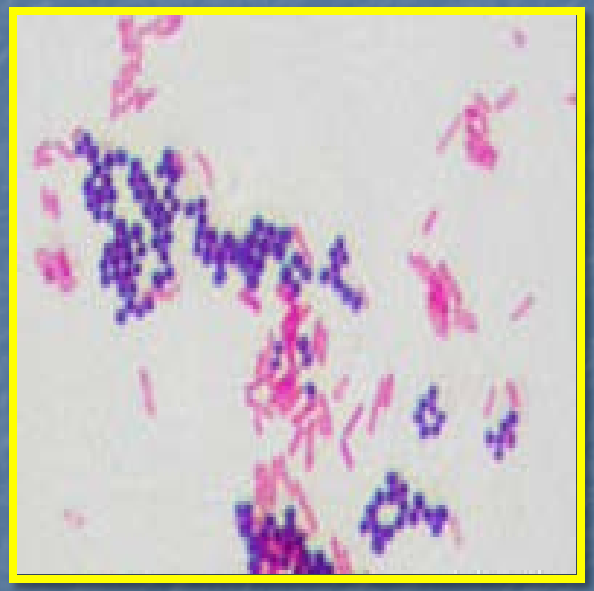

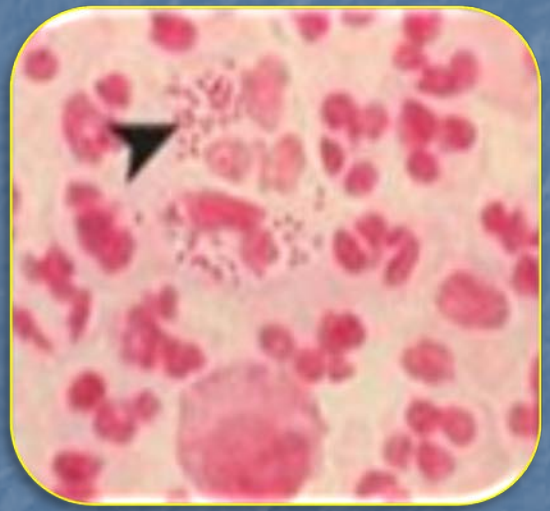

Gram Positive

Cocci

Round in clusters & tetrads:
Staphylococcus
Micrococcus
Peptococcus

Oval shape in Chains:
Streptococcus
Peptostreptococcus
Enterococcus

Bacilli

Club-shaped and/or in palisades:
Corynebacterium
Listeria
Erysipelothrix
Mycobacterium (Acid Fast)
Propionobacterium

Spore-bearing, large, uniform:
Bacillus
Clostridium

Filamentous

Extensive branching:
Actinomyces
Arachnia
Nocardia (partially acid-fast)
Streptomyces

Branching rudimentry or absent:
Erysipelothrix
Lactobacillus
Eubacterium

Gram Negative

Cocci

Neisseria
Veillonella

Bacilli

Medium-sized cocco-bacillary:
Acinetobacter
Moraxella

Tiny-cocco-bacillary:
Brucella
Bordetella
Bacteroides

Pleomorphic coccobacillary & filamentous:
Haemophilus
Bacteroides
Pasteurella
Francisella
Actinobacillus
Eikenella
Cardiobacterium
Flavobacterium

Exaggerated pointed ends:
Fusobacterium nucleatum

Coiled & sphero-plastic:
Streptobacillus
Fusobacterium

Curved, comma-shaped:
Vibrio
Campylobacter
Spirillium

Uniformly Bacillary:
Enterobacteriaceae
Pseudomonas
Aeromonas
Alcaligenes
Chromobacterium

ACID-FAST STAINING

Acid-fast staining

- This is performed on samples to demonstrate the characteristic of acid-fastness which is shared by just a few organisms
- Examples are the cysts of Cryptosporidium and certain bacteria which do not stain well with Gram (such as Mycobacteria tuberculosis) because their walls are impermeable to the dyes
- There are 3 common acid-fast staining methods
  - Ziehl Neelsen (hot)
  - Kinyoun (cold)
  - Auramine rhodamine (fluorescent)

Acid-fast theory

- Cell walls of mycobacteria contain mycolic acid, giving it a high lipid content
- High dye concentrations are required with or without heating
- The stain binds to the mycolic acid in the cell wall
- The stain can be removed with a decolourizer
- 'Acid-fast' is derived from the fact that even after addition of acid to the alcohol decolourizer, some of the stained cells retain the primary stain (carbol fuchsin) and will appear RED
- Cells that release the primary stain with decolourizing will be visible after counterstaining and will appear GREEN or BLUE

Ziehl-Neelsen stain (hot)

- Use of heat has been the reason that this technique is called the "hot staining" method
- In this method, the phenol-carbol fuchsin stain is heated to enable the dye to penetrate the waxy cell wall
- Mycobacteria such as M. tuberculosis are strongly acid-fast and will require a 3% acid alcohol for decolourizing
- The leprosy bacillus M. leprae is weakly acid-fast and will require only a 0.5-1.0% acid alcohol

Ziehl-Neelsen result

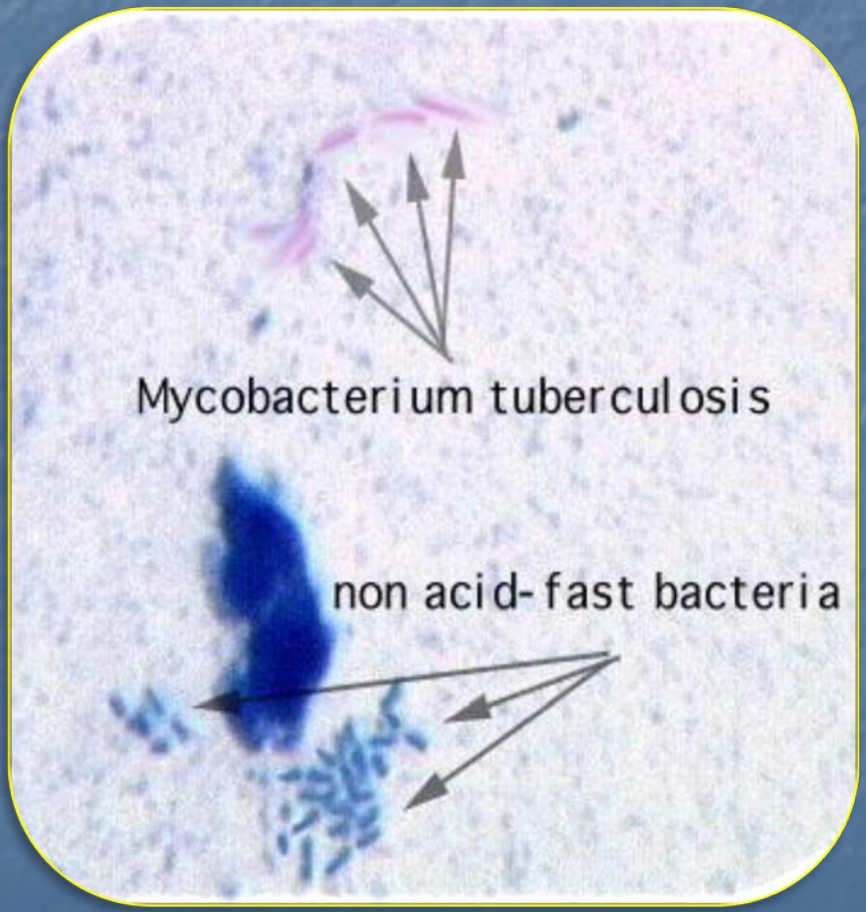

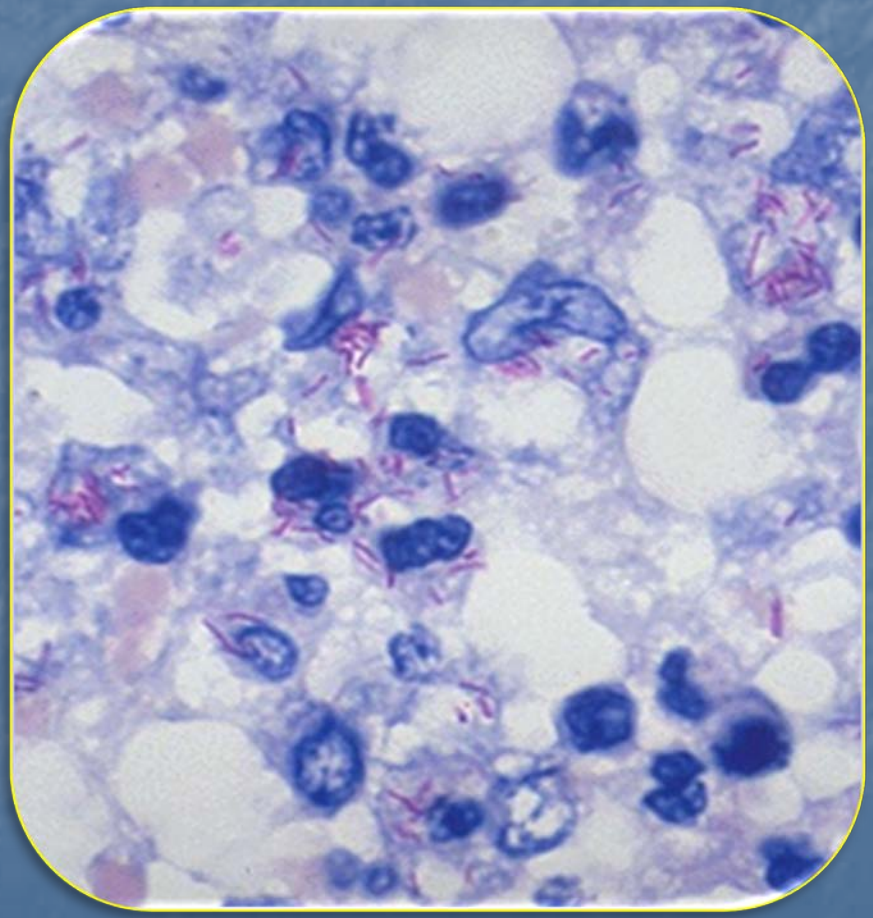

Kinyoun stain (cold)

- In the 'cold' technique, the carbol fuchsin stain is not heated
- Increased concentration of basic fuchsin and phenol plus a wetting agent (Tergitol 7) to ensure penetration

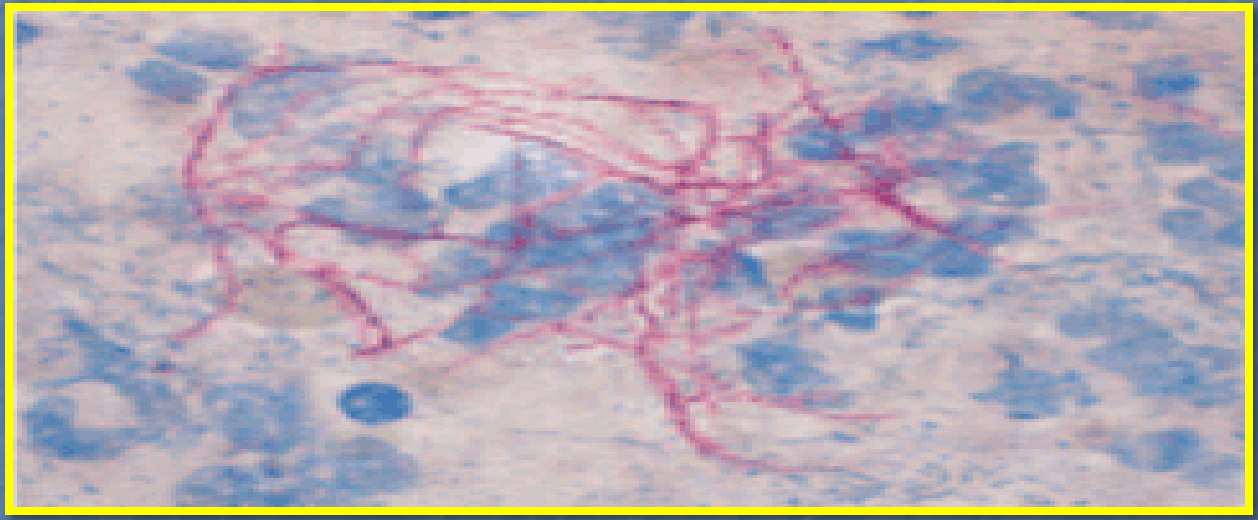

Nocardia bacteria, found in soil. Many are non-pathogenic although some species can cause respiratory infections through inhalation

Fite method for leprosy

- A ZN modification that demonstrates the acid-fast leprosy bacilli
- Method combines peanut (or mineral) oil with the solvent xylene for removing wax
- This minimizes the exposure of the cell wall to the organic solvents
- Protects the precarious acid-fastness of the organism

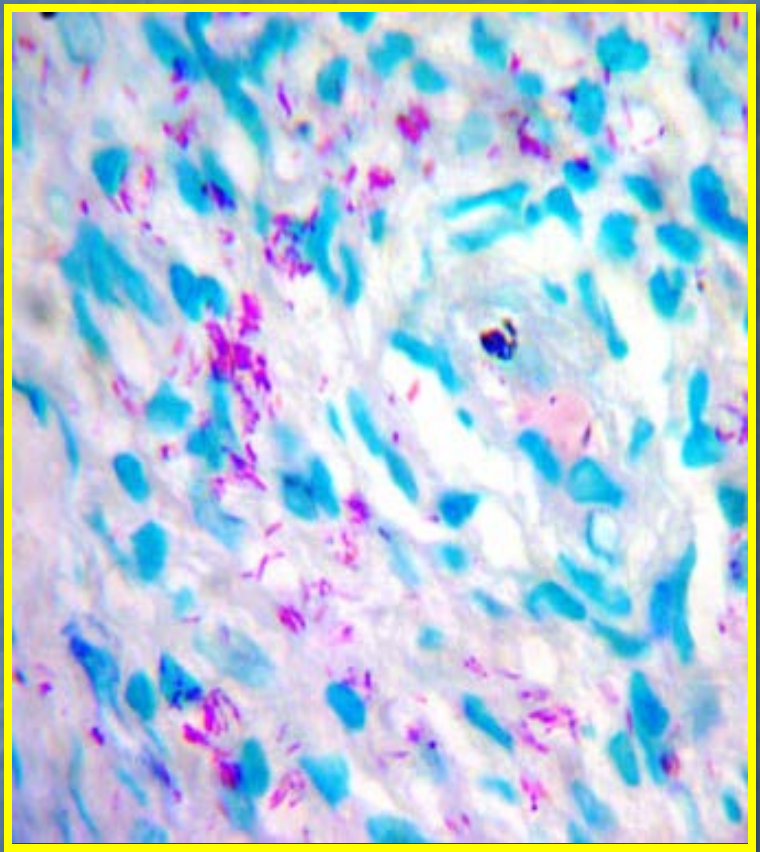

Auramine rhodamine method

- Highly specific and sensitive for mycobacteria
- Stains dead and dying bacteria not stained by the acid-fast stains
- The mycobacteria take up the dye and show a reddish-yellow fluorescence

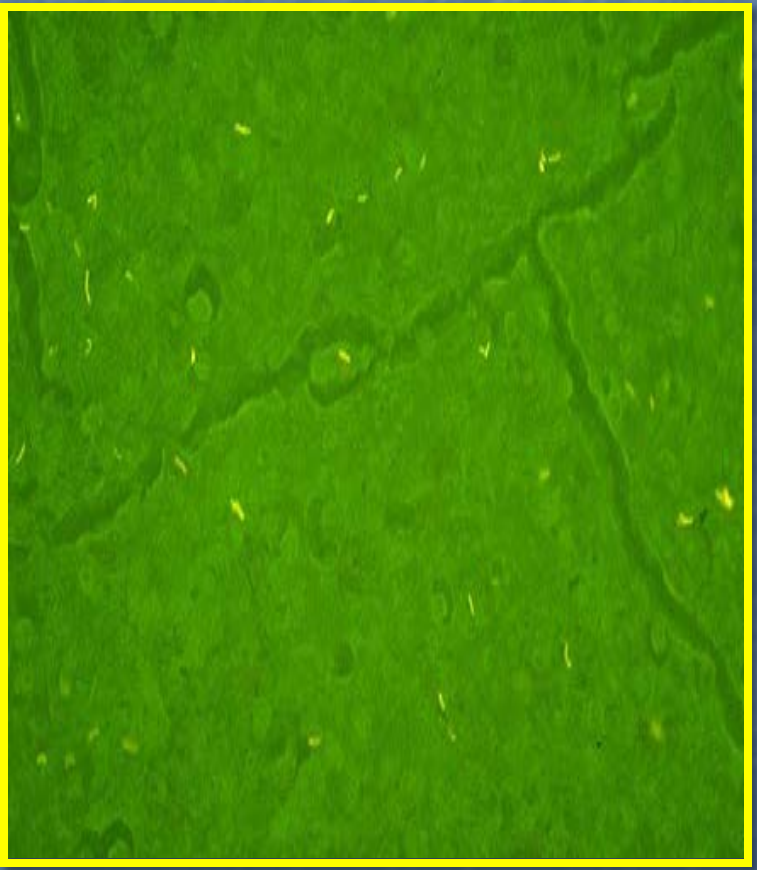

HELICOBACTER PYLORI

Helicobacter pylori

- Cause of most gastric and duodenal ulcers
- They are Gram negative bacilli and are generally 'S' shaped with four flagella
- Usually demonstrated with the Quick-Diff (or Diff-Quick), a Romanowsky type stain
- Other stains available such as Giemsa, Alcian yellow and Toluidine blue
- Use of immunochemistry



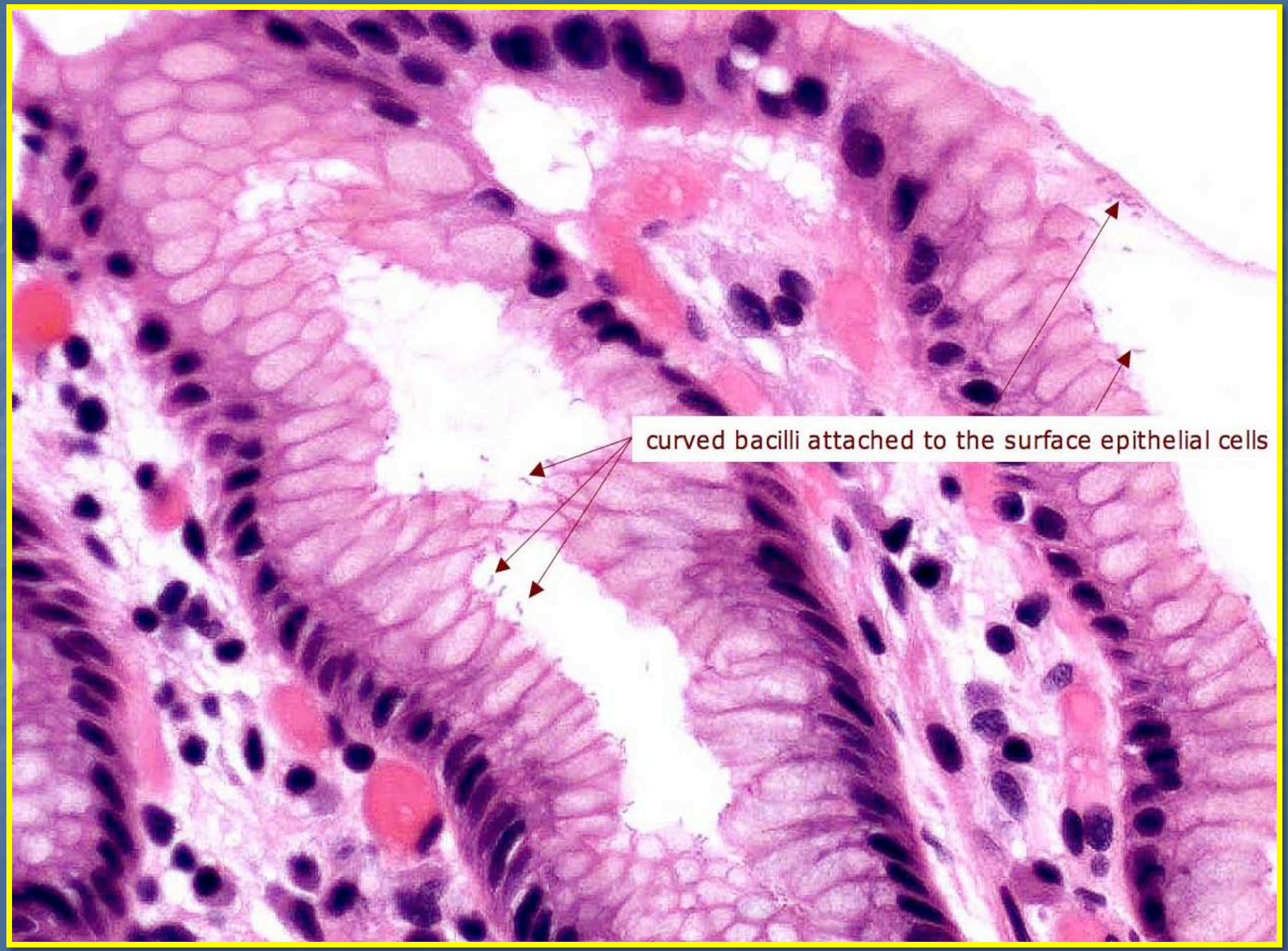
curved bacilli attached to the surface epithelial cells

Quick-Diff stain

- Romanowsky-type stain

  Reagent A - Buffered eosin

  Reagent B - Buffered methylene blue

  Buffer - Sorensen's or phosphate buffer pH6.8

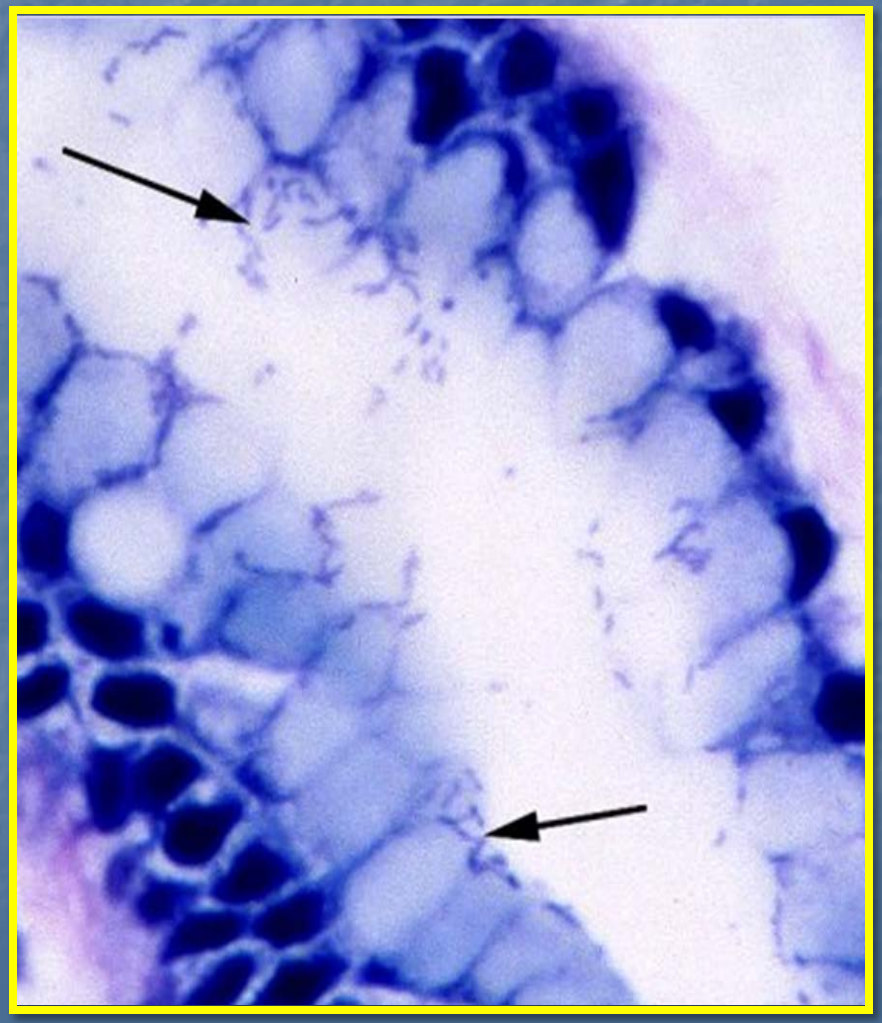

Steiner method

- Silver impregnation method
- Several modifications
- Purchase in kit form

Solution A: Zinc Formalin Sensitizer

Solution B: Silver Nitrate, 1%

Solution C: Gum Mastic, 2.5%

Solution D: Hydroquinone, 0.5 gm

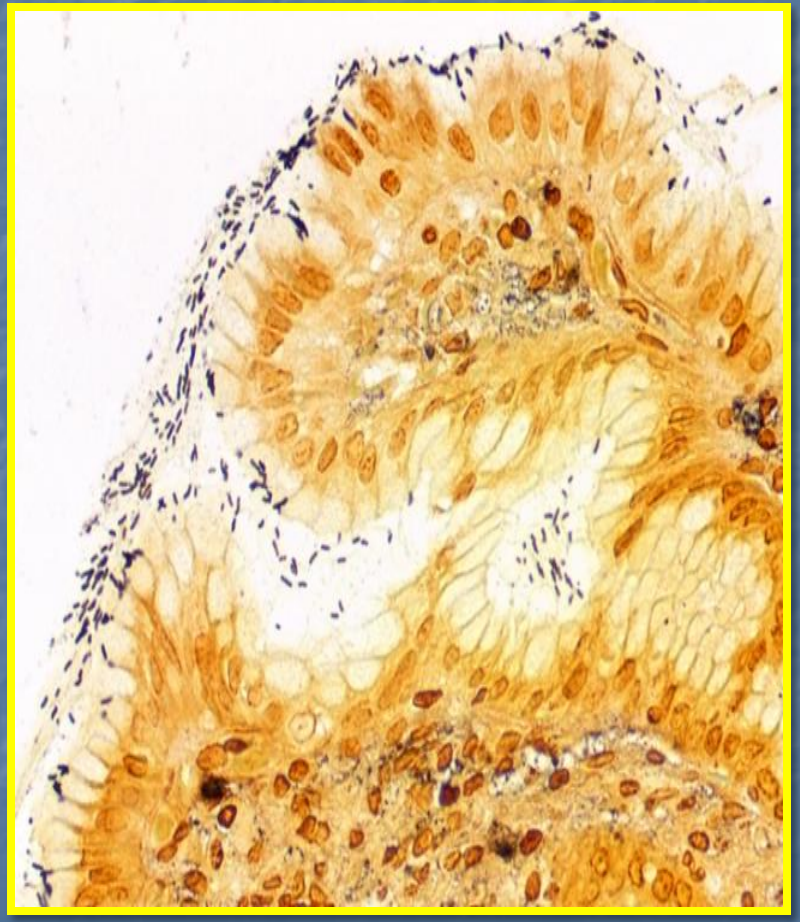

Immunochemistry

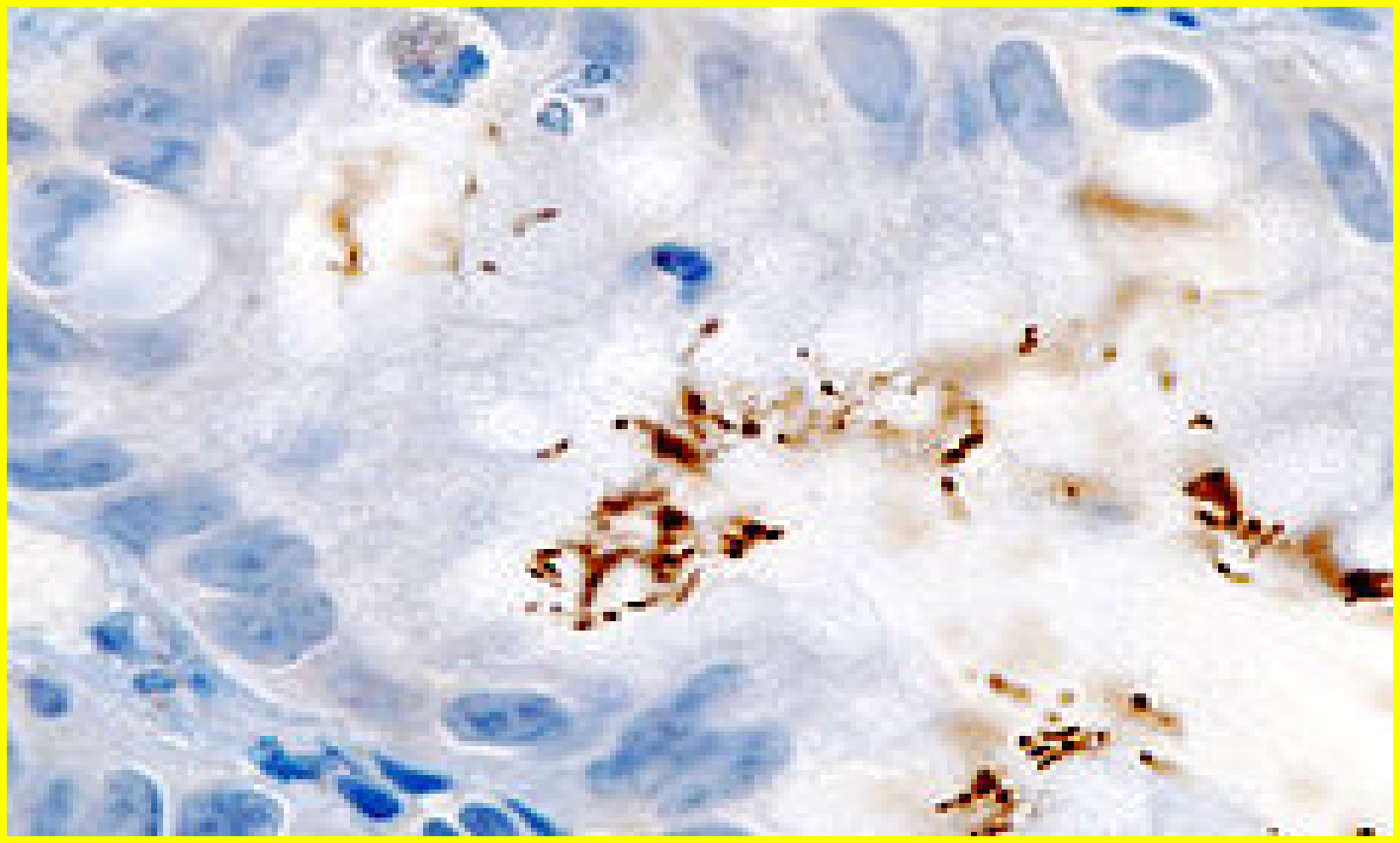

SPIROCHAETES

Spirochaetes

- These are spiral in shape
- Treponema pallidum is Gram negative and causes syphilis
- Stain with a variety of silver stains such as Warthin-Starry, Dieterle, Hage-Fontana and Steiner methods
- Can stain elastic tissue and affect interpretation
- Spirochaetes can be viewed in skin scrapings under dark field microscopy

Stains for spirochaetes

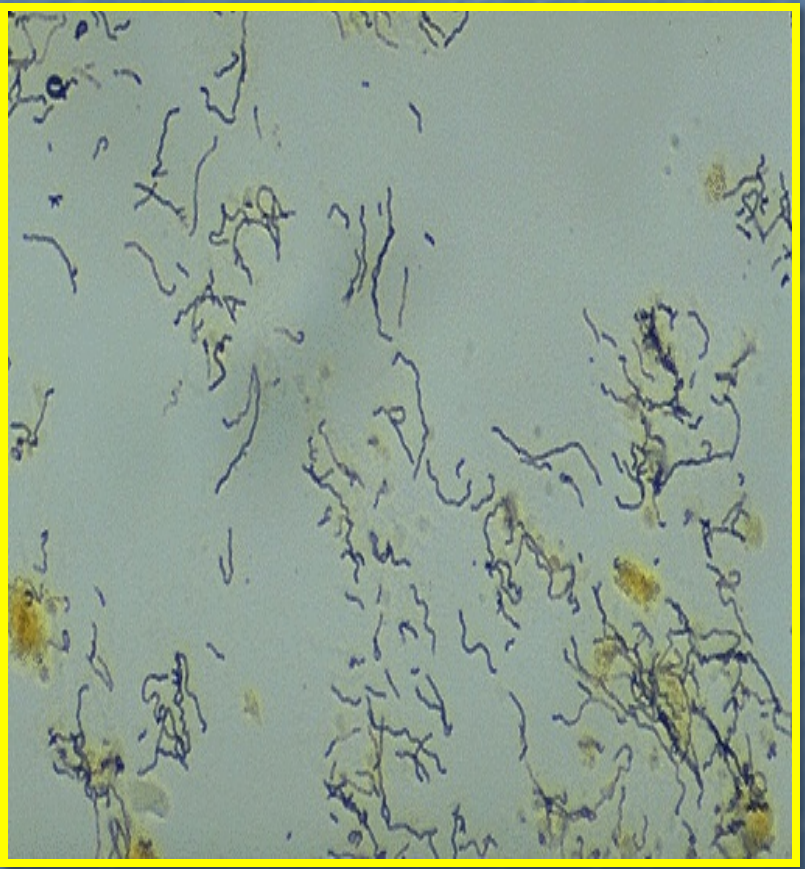

Warthin-Starry

Hage-Fontana

2

PROTOZOA

PROTOZOA

- These are a diverse group of unicellular organisms, many of which are motile
- They are restricted to moist or aquatic habitats
- Many species are parasites and some are predators of faeces, bacteria and algae
- There are an estimated 30,000 protozoan species

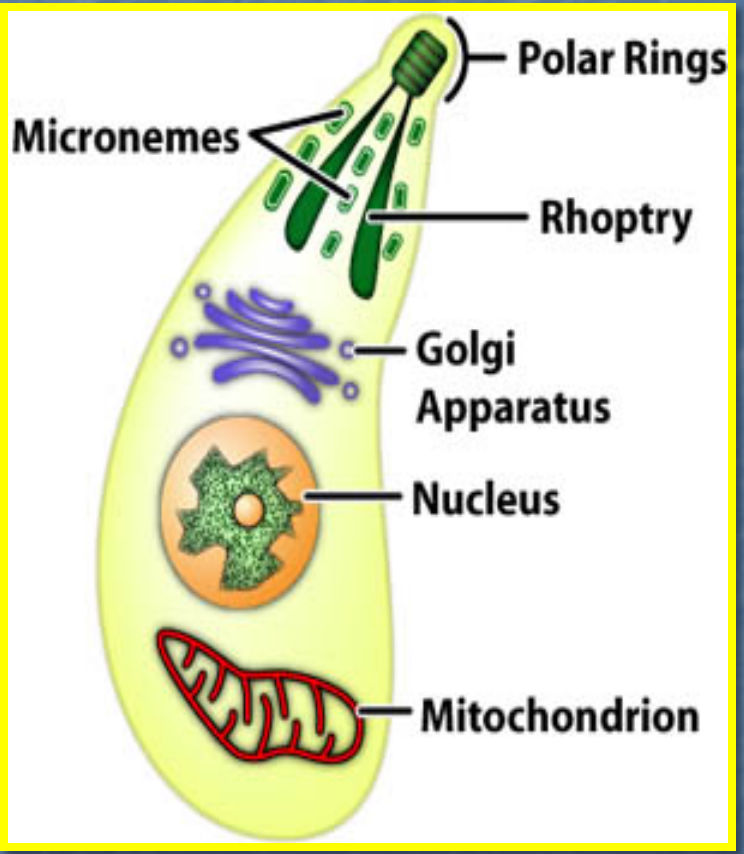

PROTOZOA

- Intestinal protozoa

  e.g. Entamoeba histolytica, Cryptosporidium parvum, Giardia lamblia

- Urogenital protozoa

  e.g. Trichomonas vaginalis

- Blood and tissue protozoa

  e.g. Toxoplasma gondii, Plasmodium falciparum

PROTOZOA

- Intestinal protozoa

  e.g. Entamoeba histolytica, Cryptosporidium parvum, Giardia lamblia

- Urogenital protozoa

  e.g. Trichomonas vaginalis

- Blood and tissue protozoa

  e.g. Toxoplasma gondii, Plasmodium falciparum

Intestinal protozoa

- Entamoeba histolytica
- Causes amoebic dysentery
- Frequent in wartime and in travellers to endemic areas
- Can cause liver abscesses
- Can be demonstrated using the trichrome stain

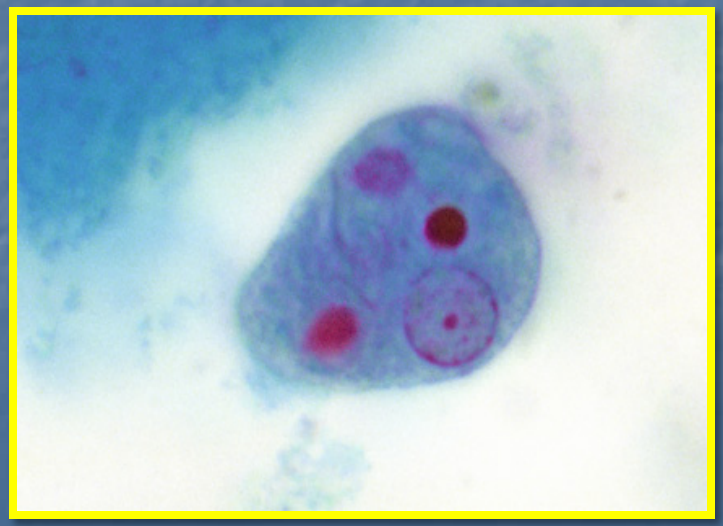

- Cryptosporidium parvum
- Causes watery diarrhoea
- Waterborne disease
- Immunodeficienct patients may be unable to clear the parasite and may be fatal
- Stains with Kinyoun (cold ZN)

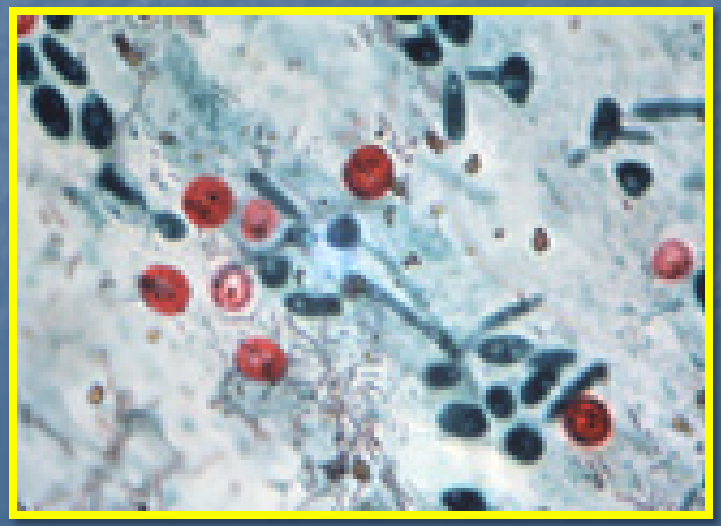

Giardia lamblia (intestinalis)

- Giardia is a protozoa that can infect the bowel
- Causes giardiasis which can lead to chronic diarrhoea
- May form cysts in bowel
- Spread in poorly treated water contaminated with infected faeces
- Most commonly occurs in countries that have poor sanitation (beaver fever)

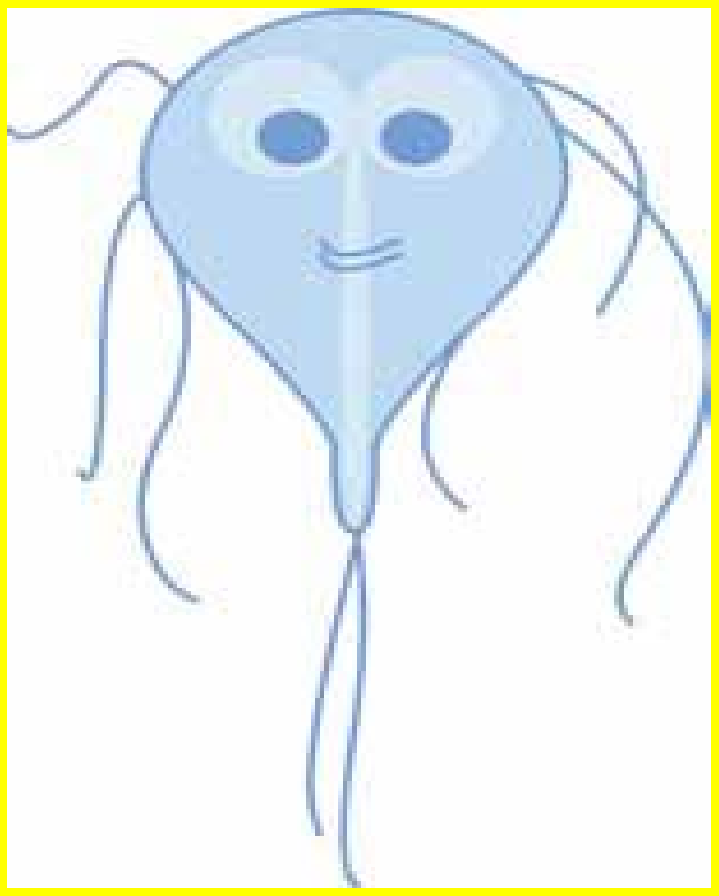

Giardia

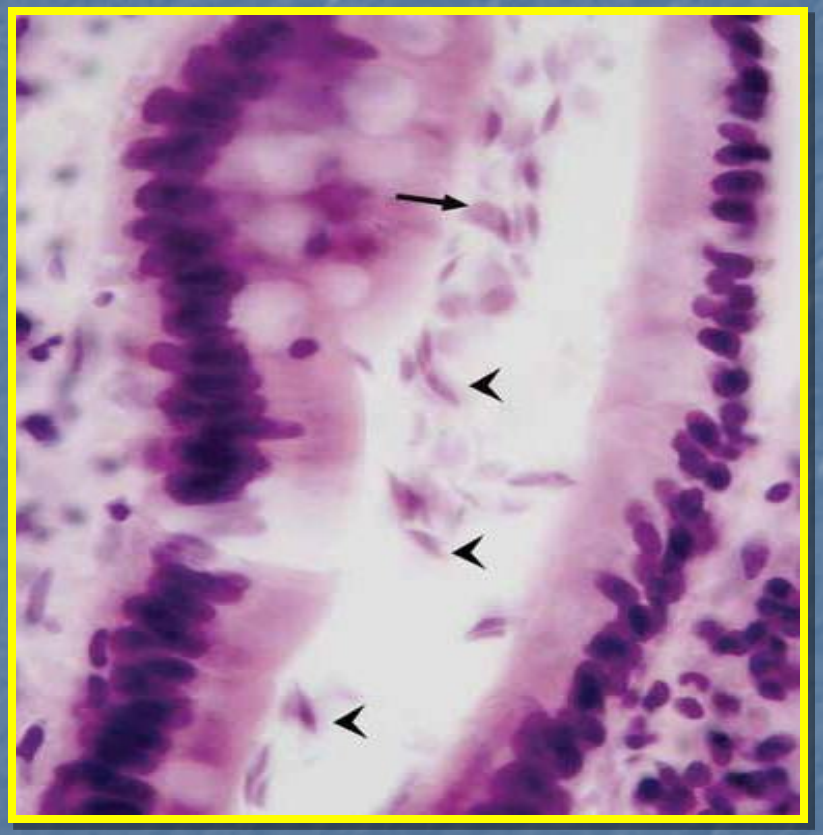

H&E shows appearance of tumbling leaves.
Some organisms show faint nuclei

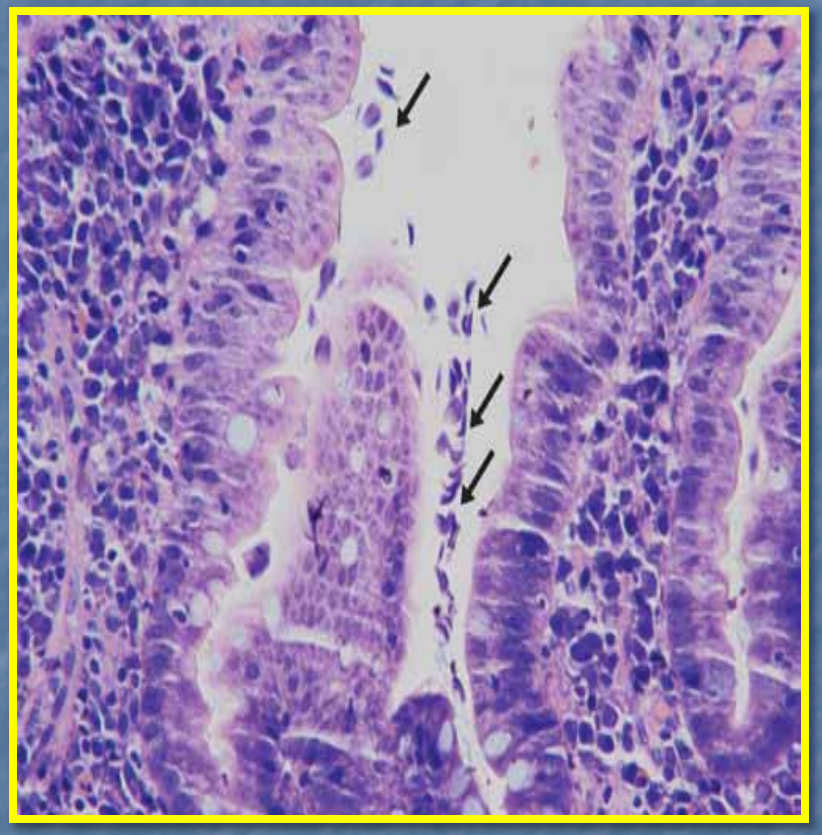

Giemsa

PROTOZOA

- Intestinal protozoa

  e.g. Entamoeba histolytica, Cryptosporidium parvum, Giardia lamblia,

- Urogenital protozoa

  e.g. Trichomonas vaginalis

- Blood and tissue protozoa

  e.g. Toxoplasma gondii, Plasmodium falciparum

Trichomonas vaginalis

- Sexually transmitted flagellate protozoa
- Common cause of genito-urinary tract infections in both sexes eg. urethritis
- In women, it may cause vaginitis
- Can be identified in cervical smears and stains with Giemsa

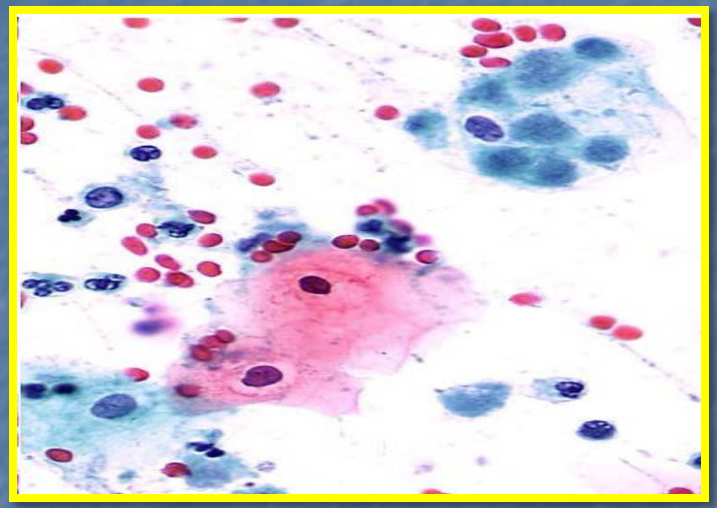

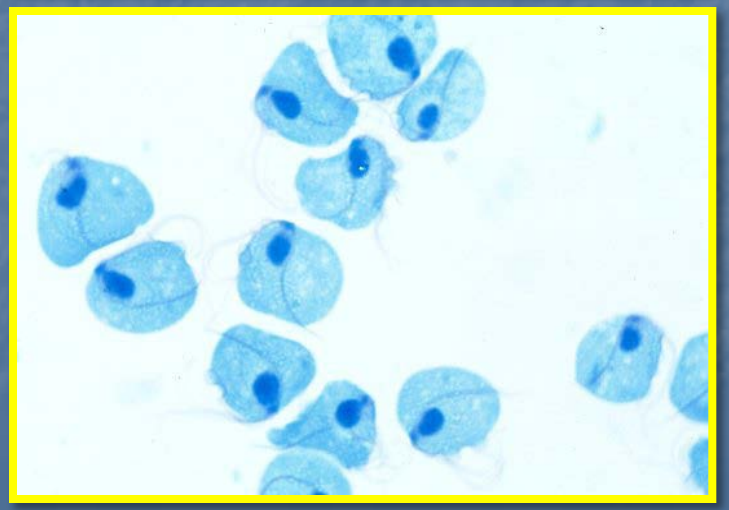

PROTOZOA

- Intestinal protozoa

  e.g. Entamoeba histolytica, Cryptosporidium parvum, Giardia lamblia

- Urogenital protozoa

  e.g. Trichomonas vaginalis

- Blood and tissue protozoa

  e.g. Toxoplasma gondii, Plasmodium falciparum

Blood and tissue protozoa

- Toxoplasma gondii
- Causes intrauterine infections such as congenital disorders from acute infection of mother during pregnancy
- Cats are natural hosts
- Babies may have significant pathology in later life

- Plasmodium species
- Causes malaria
- There are four main species of that cause disease: Plasmodium vivax, P. ovale, P. malariae and P. falciparum, the most important
- Carried by mosquitoes
- Diagnosis is made by visualizing parasites invading red blood cells

3

HELMINTHS

Helminths

- Large, multicellular, worm-like organisms, often seen with the naked eyes in mature stages
- Receive food and protection from living hosts
- Cause illness and disease

- Cestodes (tapeworms)
- Nematodes (roundworms)
- Trematodes (flukes)

- Ringworm is caused by a fungus and not by a parasitic worm

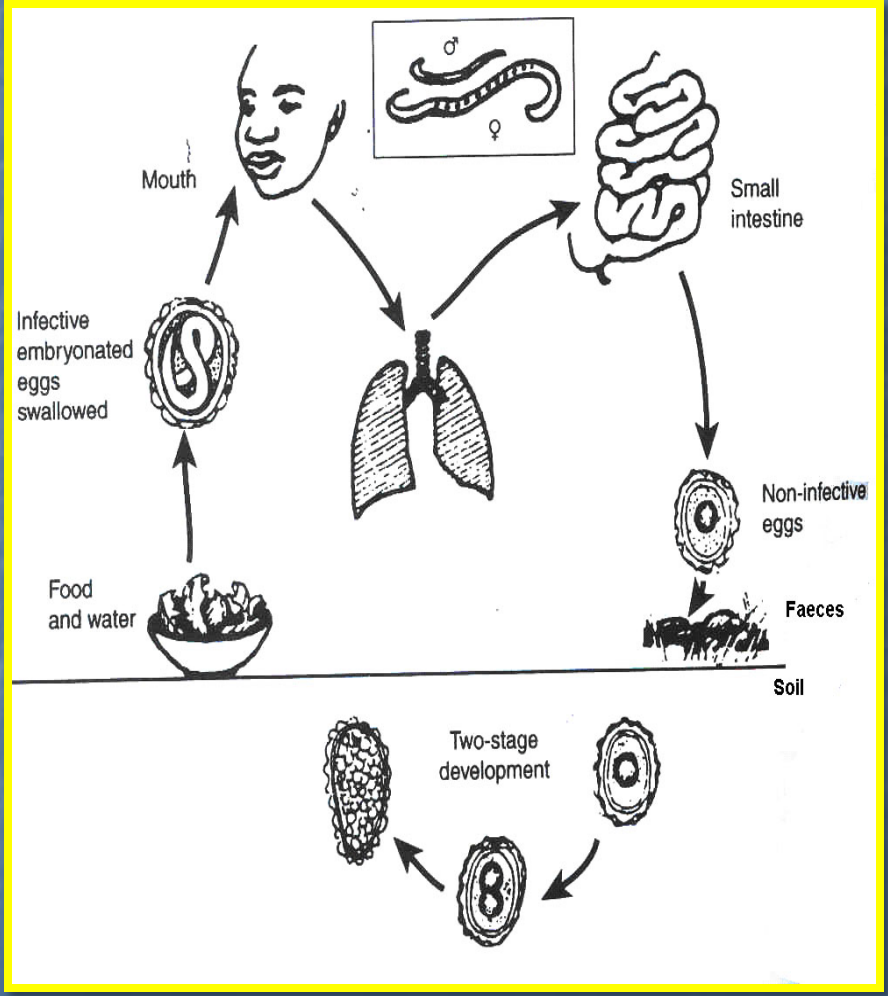

	Cestodes (tapeworms)	Trematodes (flukes)	Nematodes (roundworms)
Shape	Segmented plane	Unsegmented plane	Cylindrical
Body cavity	No	No	Present
Body covering	Tegument	Tegument	Cuticle
Digestive tube	No	Ends in caecum	Ends in anus
Sex	Hermaphroditic	Hermaphroditic, except schistosomes which are dioecious	Dioecious
Attachment organs	Sucker or bothridia and rostellum with hooks	Oral sucker and ventral sucker or acetabulum	Lips, teeth, filariform extremities, and dentary plates
Diseases in humans	Tapeworm infection	Schistosomiasis	Ascariasis, dracunculiasis, elephantiasis, enterobiasis (pinworm), filariasis, hookworm, onchocerciasis, trichinosis, trichuriasis (whipworm)

Schistosomiasis

- Known as bilharzia, snail fever and Katayama fever, it is caused by Schistosoma worm
- Can infect the urinary tract and intestines
- Causes liver and kidney damage and linked to bladder cancer
- Spread by contact with water that contains the parasites
- Parasites are released from infected freshwater snails



Schistsomiasis

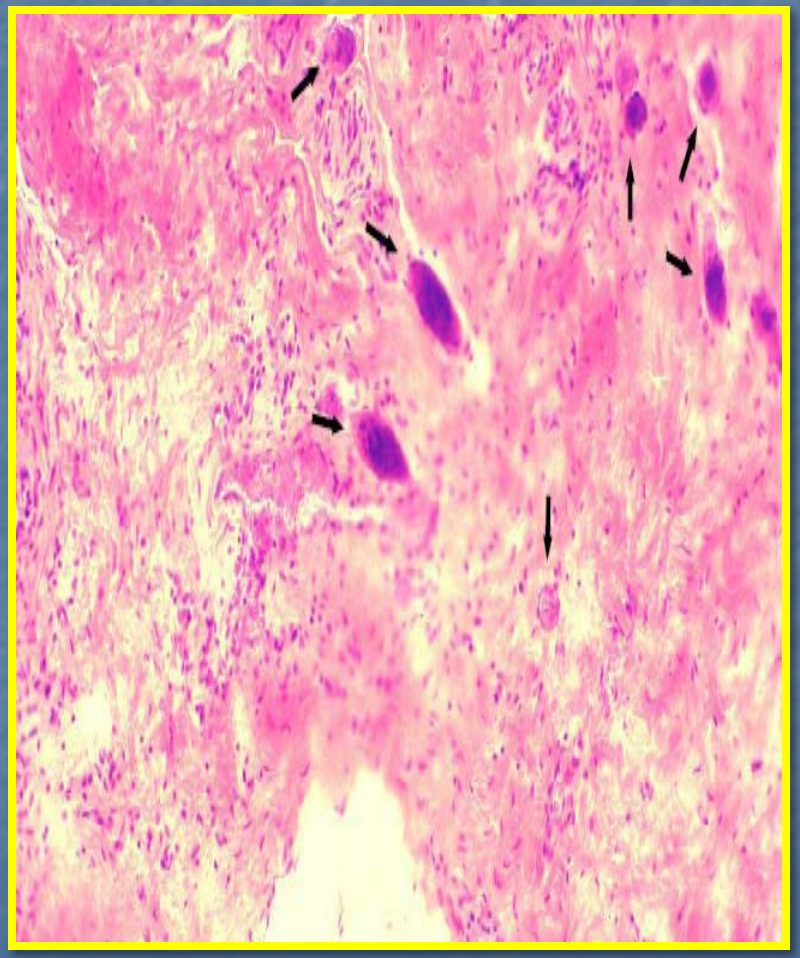

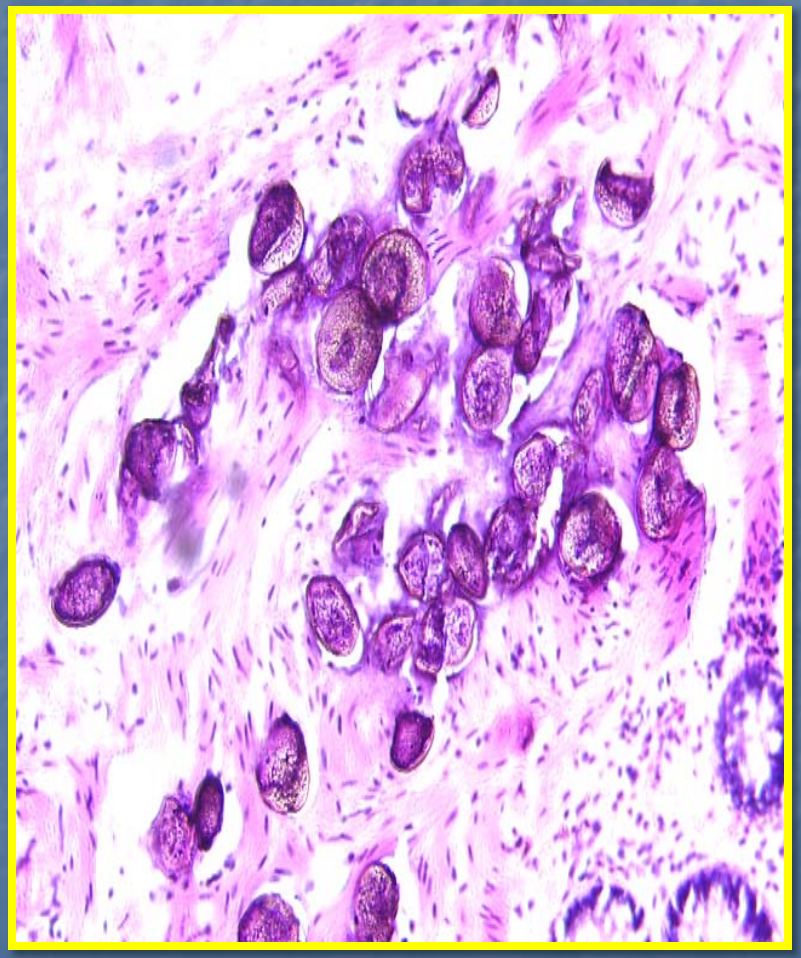

4

FUNGI

FUNGI

- The presence of fungus in the tissue sections provides evidence of invasive infection
- Because of their size and morphologic diversity, many fungi can be seen in conventional H&E sections
- In tissues, fungi usually occur either as hyphae, budding yeast spherules or a combination of them
- Evaluation of granulomatous inflammation must include special stains to exclude presence of fungi (and acid-fast bacteria)
- Methenamine Silver (GMS) , Gridley's method and Periodic acid-Schiff (PAS) are the most common stains
- Always use positive control slides

Methenamine Silver (Gomori, Grocott)

- Also known as GMS, involves oxidization in chromic acid
- Methenamine (hexamine) silver solution at 60°C
- Tone in gold chloride and fix in sodium thiosulphate (hypo)
- Counterstain in light green
- Fungi stain black
- With pneumocystis, the cell walls are stained, so organisms are outlined by the black stain

Gridley's method

- Modified PAS stain
- Oxidize in chromic acid for 1 hour
- Schiff reagent 10-15 mins
- Wash in water
- Haematoxylin counterstain

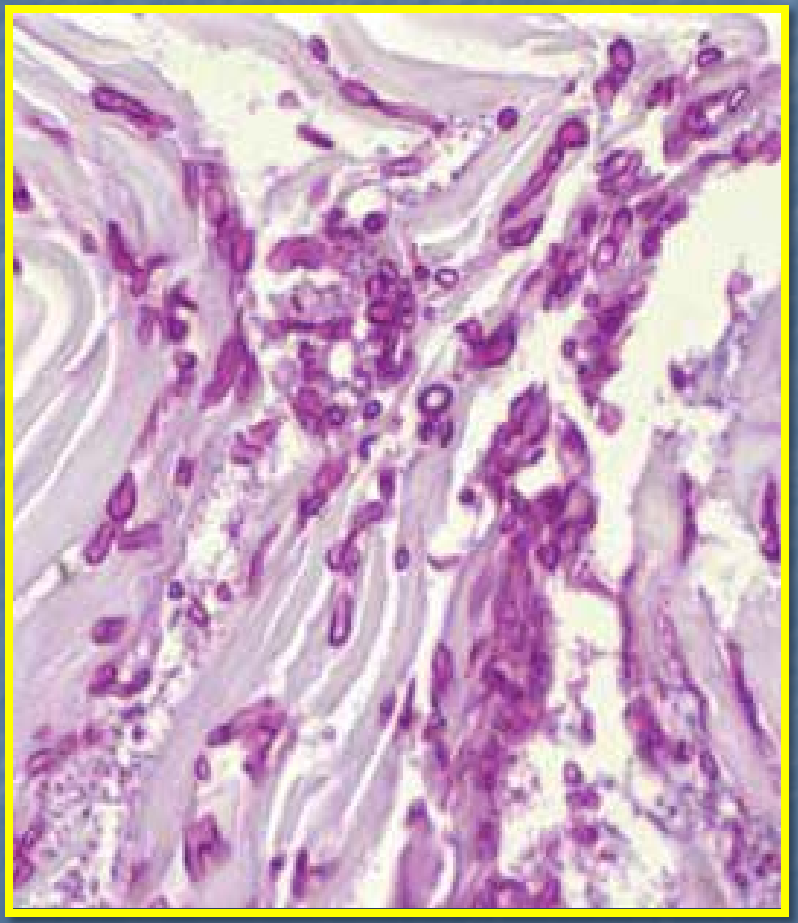

Important fungi

- Aspergillus
- A. fumigatis found in soil and compost heaps
- Commonly causes disease in immunodeficiency such as AIDS and transplant patients
- Can infect lungs and cause chronic infections
- Common cause of death

- Candida
- Most common fungal infection
- Found on mucous membranes
- C. albicans can infect skin, throat and genitals and cause thrush and candidiasis
- Many found in gut flora

Aspergillus

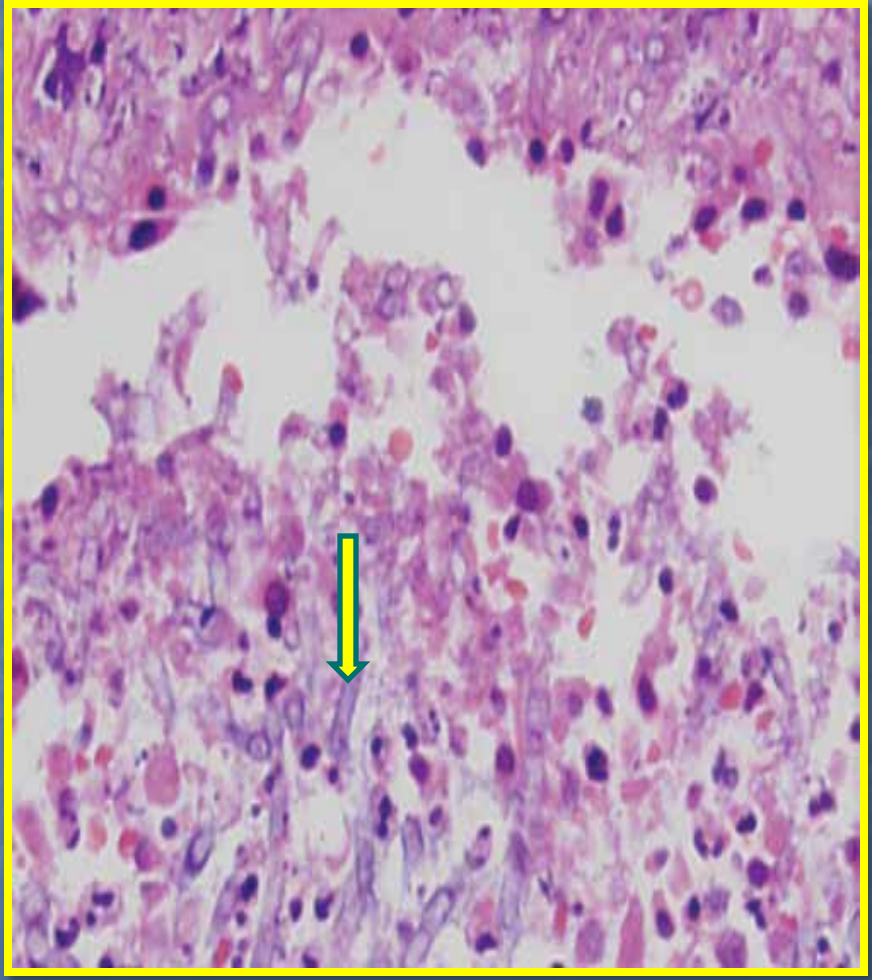

Haematoxylin & eosin

Methenamine silver

Candida albicans

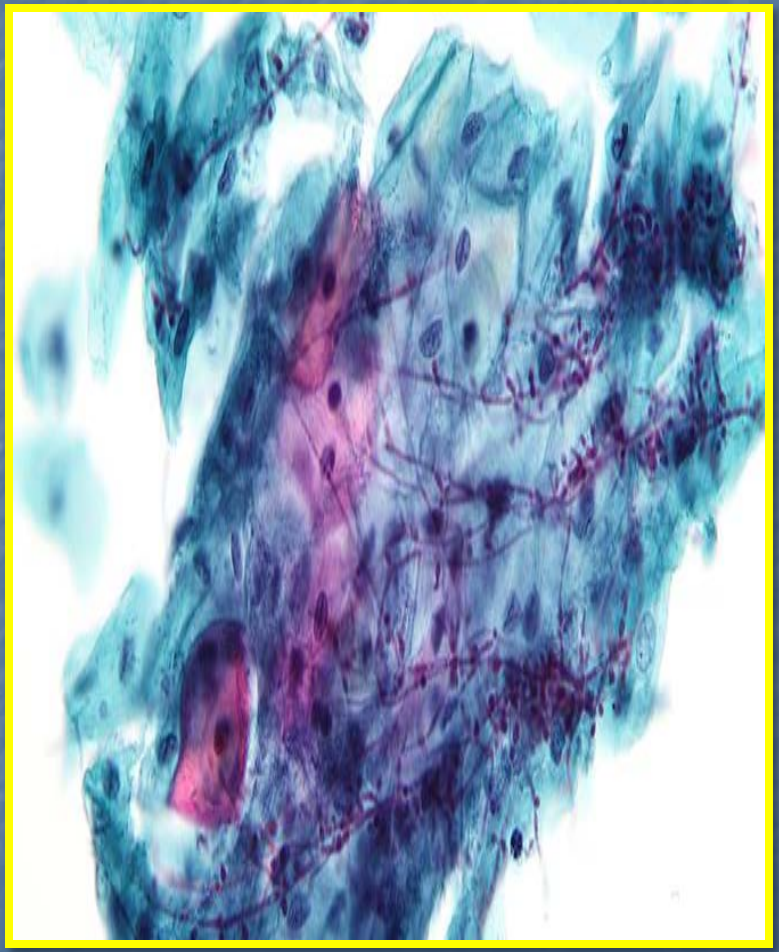

Papanicoloau stain

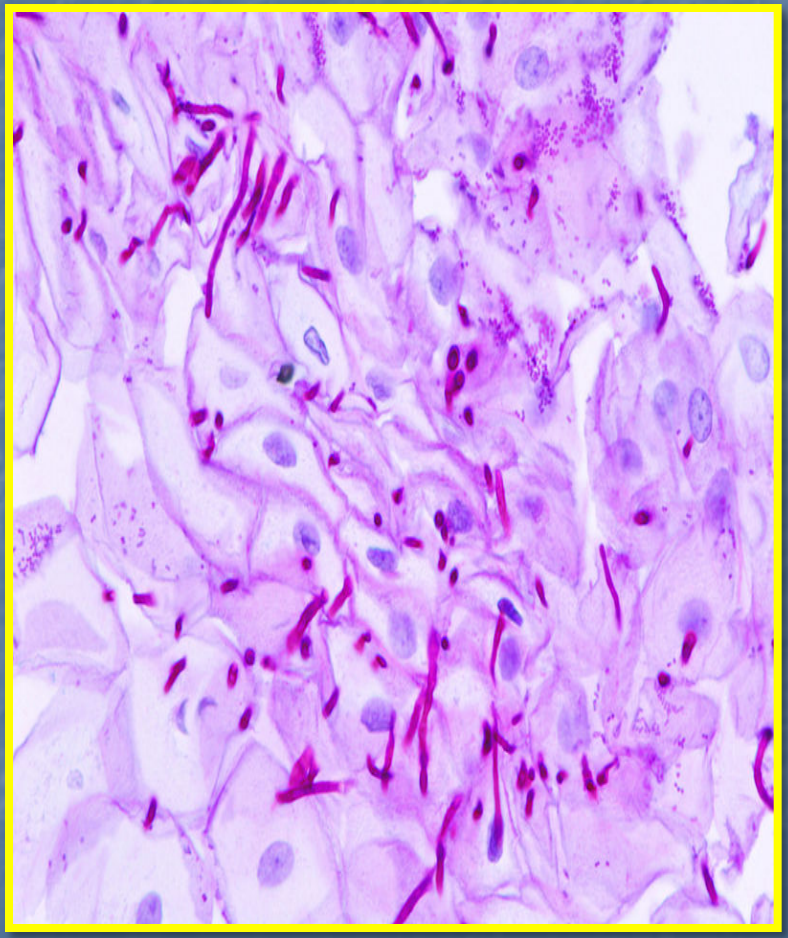

PAS stain

Important fungi

- Cryptococcus
  - C. neoformans found in soil and bird droppings
  - Spread by inhalation of spores
  - Causes lung infections
  - May spread to nervous system and cause encephalitis
- Pneumocystis jirovecii
  - Formerly pneumocystis carinii
  - Commonly found in healthy lungs but can cause infections in immunosuppressed patients
  - Causes PCP (pneumocystis pneumonia), often found in patients on chemotherapy

Cryptococcus

Gridley's method

Methenamine silver

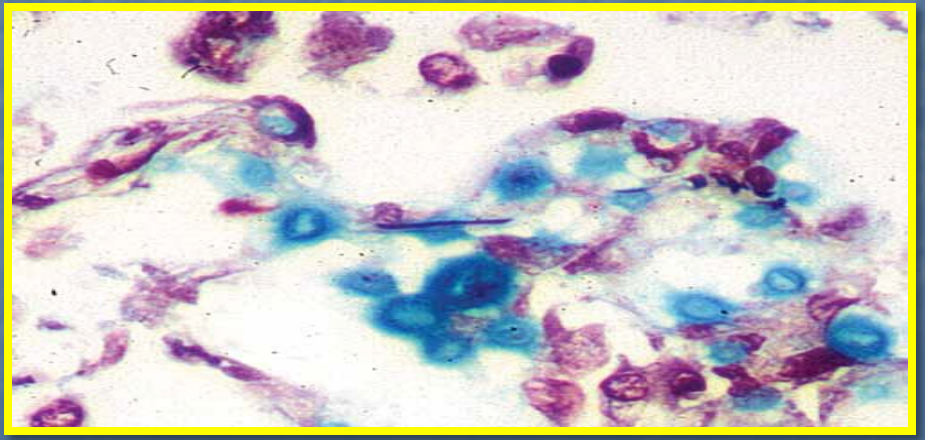

Alcian blue

Pneumocystis

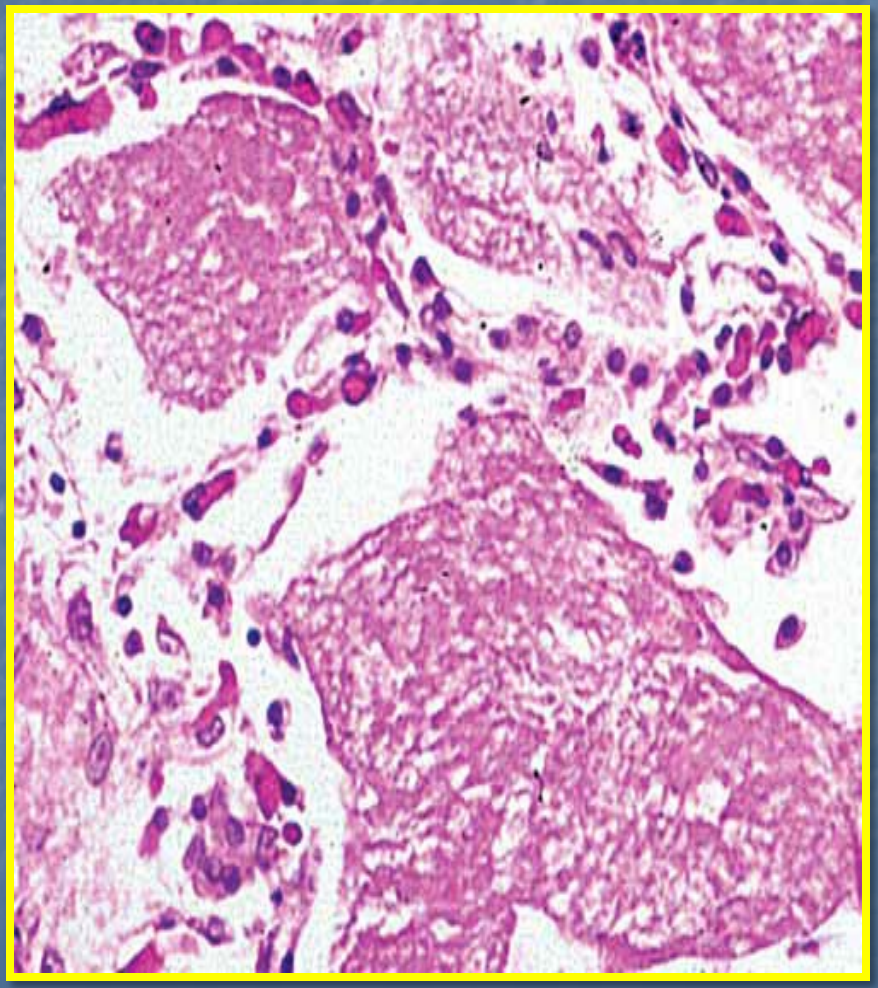

Haematoxylin & eosin

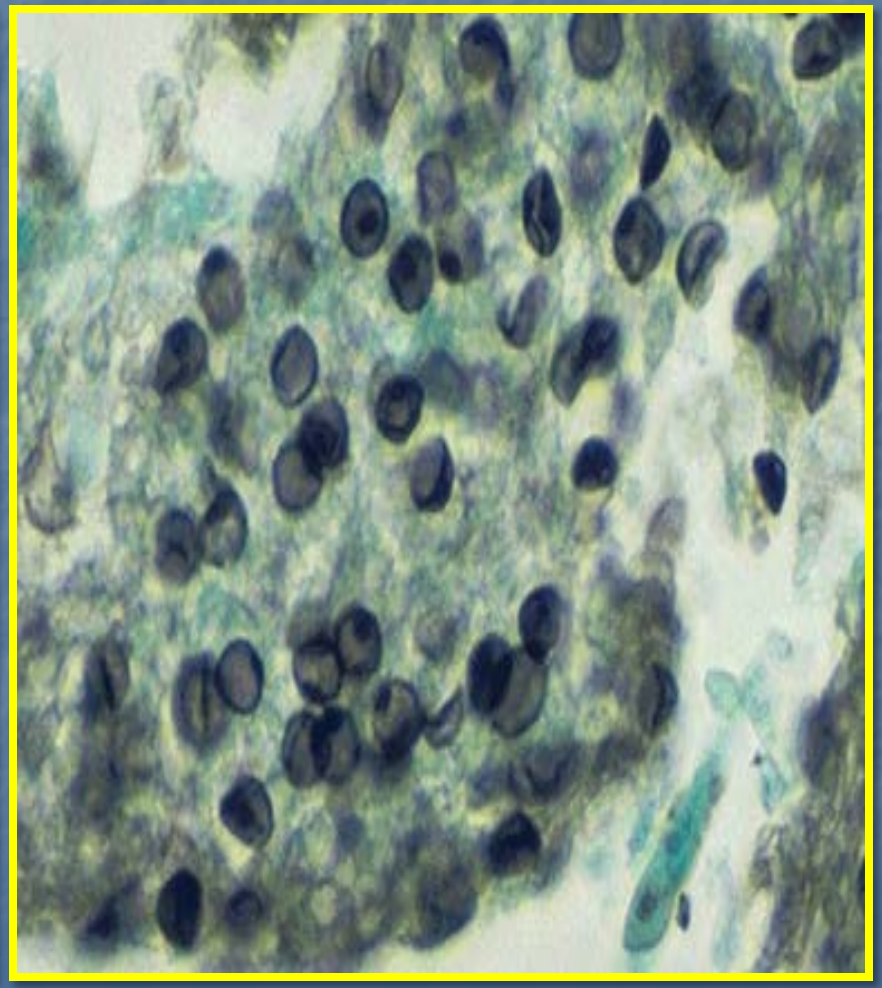

Methenamine silver

Use of fluorescence

- Autofluorescence
- Some fungi in the H&E are autofluorescent under UV
- Candida and aspergillus appear yellow-green
- With PAS, they appear bright yellow against deep orange-red background

- Direct immunofluorescence
- This can be performed on smears and paraffin sections
- Prolonged storage does not affect antigenicity of fungi
- Allows retrospective studies and shipment to distant sites for confirmatory identification

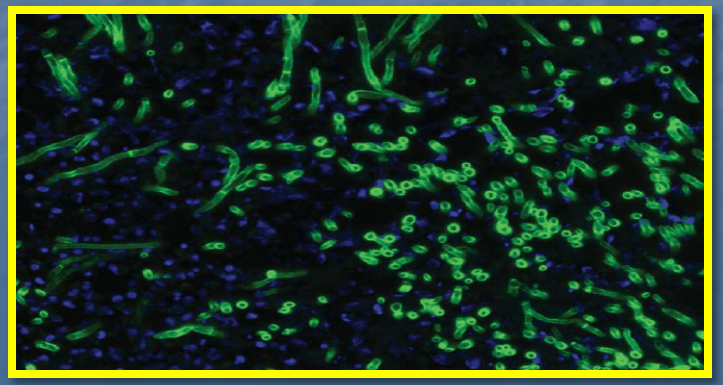

5

VIRUSES

Viral inclusion bodies

- Detection of viral inclusion bodies using special stains like Giemsa or Macchiavello, which uses basic fuchsin, citric acid and methylene blue
- These are abnormal structures which appear within the cell nucleus, cytoplasm or both during virus multiplication
- The presence of inclusion bodies may often be seen on H&E stain
- Important in diagnosis

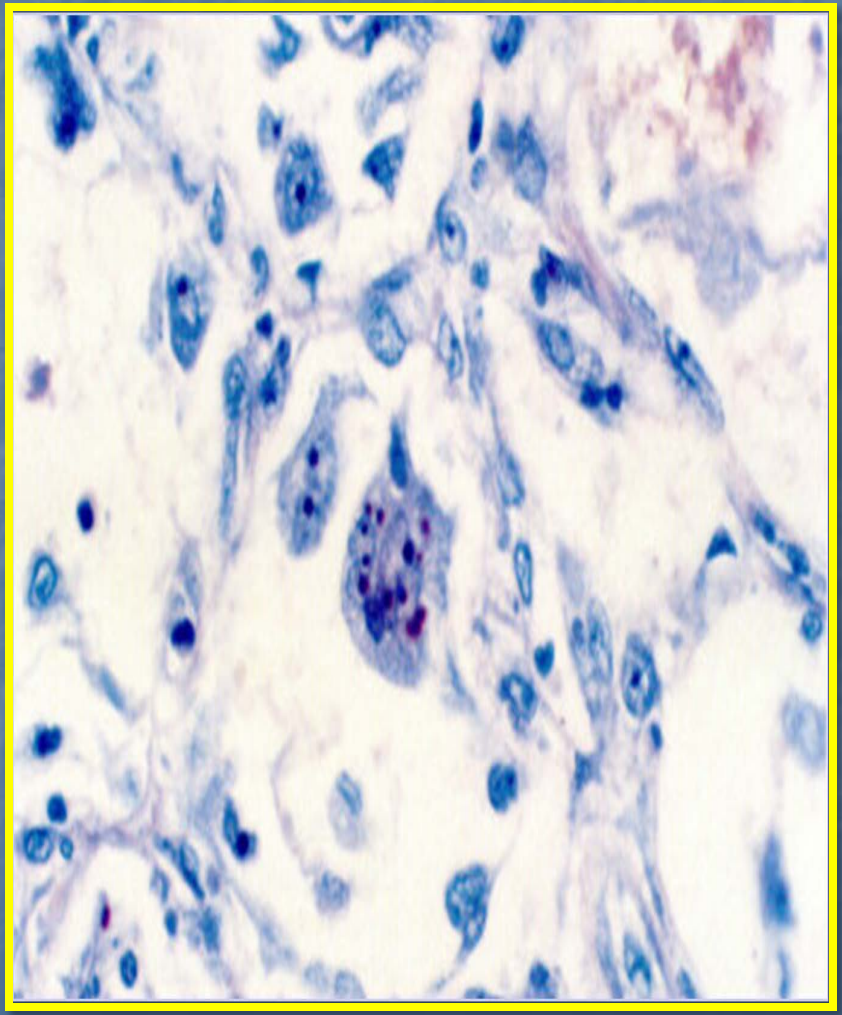

Hepatitis (Australia antigen)

- HBsAg is the surface antigen of the hepatitis B virus
- It indicates current hepatitis B infection
- Known as Australia antigen, it was first demonstrated in an Australian aborigine
- It can be demonstrated with the Shikata orcein method (which also stains the elastic tissue)

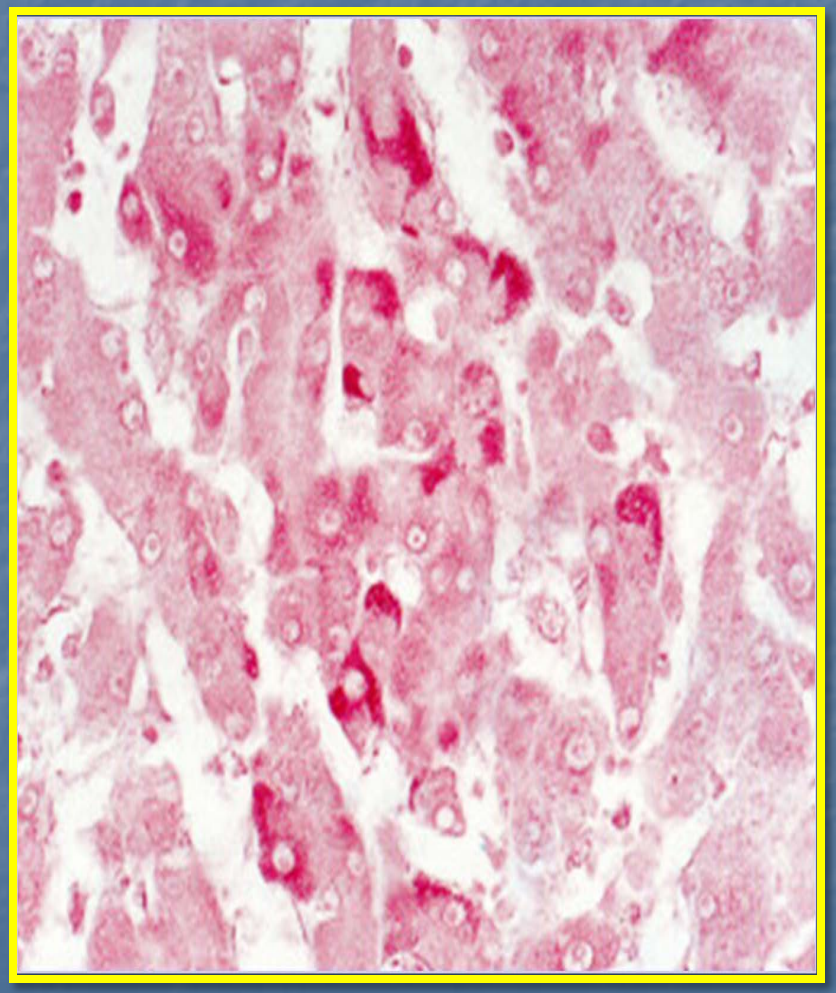

Herpes virus (Cowdry bodies)

- Type 1 produces recurrent blisters around the lips and generalized infections in older children and adults
- Type 2 infection affects the genital tract
- Inclusion bodies do not appear until after the virus has multiplied
- Cowdry bodies appear as intranuclear eosinophilic inclusions in infected cells

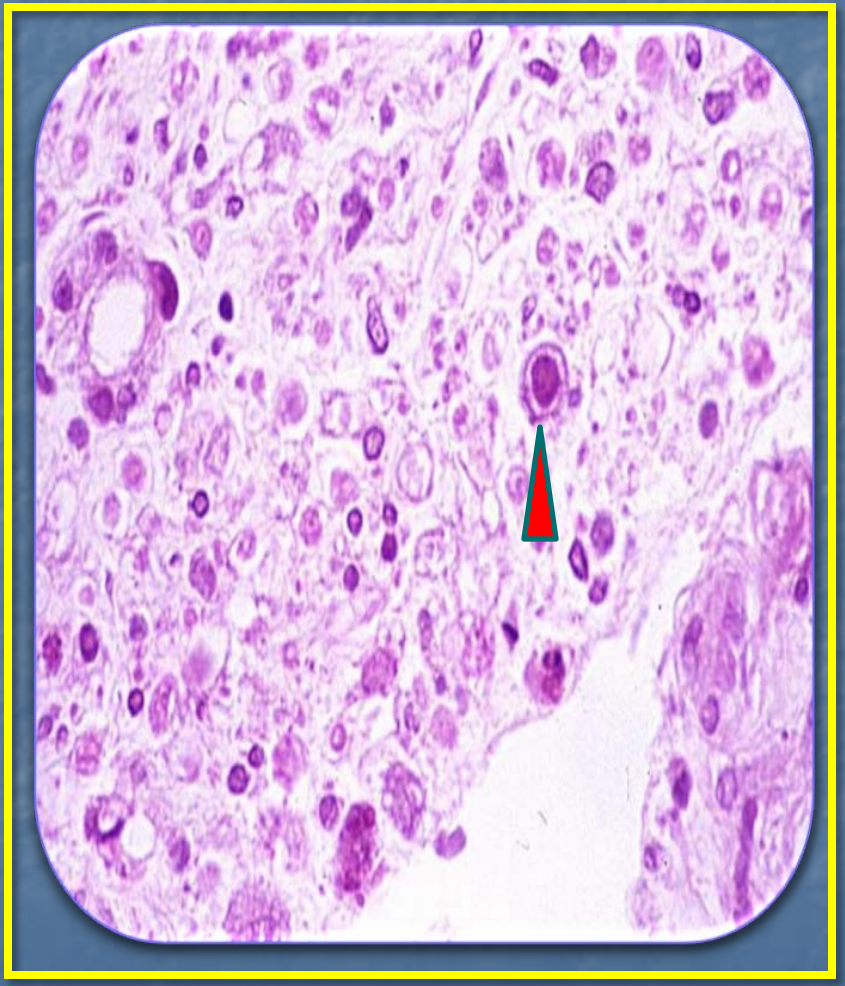

Rabies (Negri bodies)

- Caused by the rabies virus
- The disease is spread by infected animals such as dogs, bats and monkeys
- Negri bodies are round or oval inclusions within the cytoplasm of nerve cells (frequently the Purkinje cells)
- Diagnostic of rabies

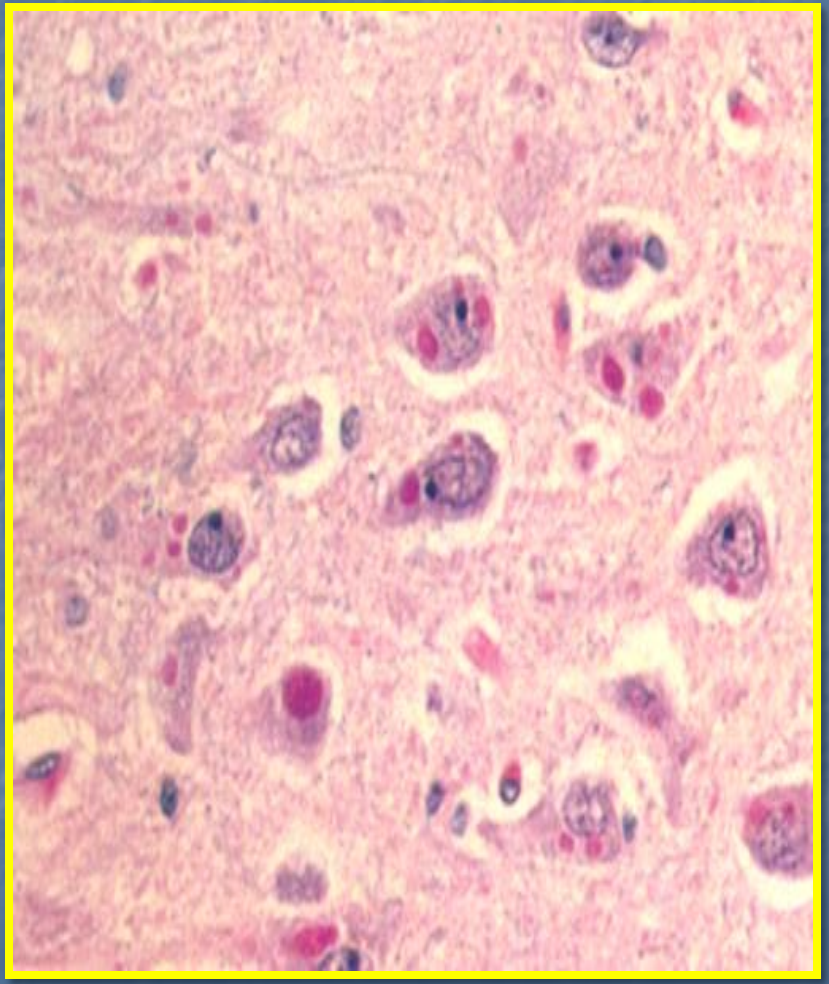

Molluscum contagiosum

- This is a common non-cancerous growth caused by infection with the poxvirus
- Henderson-Patterson bodies are eosinophilic, cytoplasmic inclusions in the cells of the uppermost layers of the skin
- They are masses of maturing virus particles and can be seen with H&E stain



Human
Papillomavirus
(HPV)



Viral proteins are expressed in a highly organized pattern as an infected cell migrates towards the surface

Genital infections