Lipids

Dr Phil Bryant, Wales, UK

Lipids

- Lipids are structural components of cell membranes
- Lipids store energy
- Lipids form the basis of hormones

LIPIDS

Simple lipids

Esters of fatty acids

- **Fats**: Esters of fatty acids and glycerol
- **Waxes**: Esters of long chain fatty acids and longchain alcohols

Compound lipids

Esters of fatty acids and alcohol contain other groups also

Phosphatides (lecithin, cephalin, sphingomyelin)

Cerebrosides (glycolipids & galacto-lipids such as kerasine and phrenosine)

Derived lipids

Composed of hydrocarbon rings and a long hydro-carbon side chain

Fatty acids (saturated and unsaturated)

Alcohols (sterols such as cholesterol)

Fat cells - adipocytes

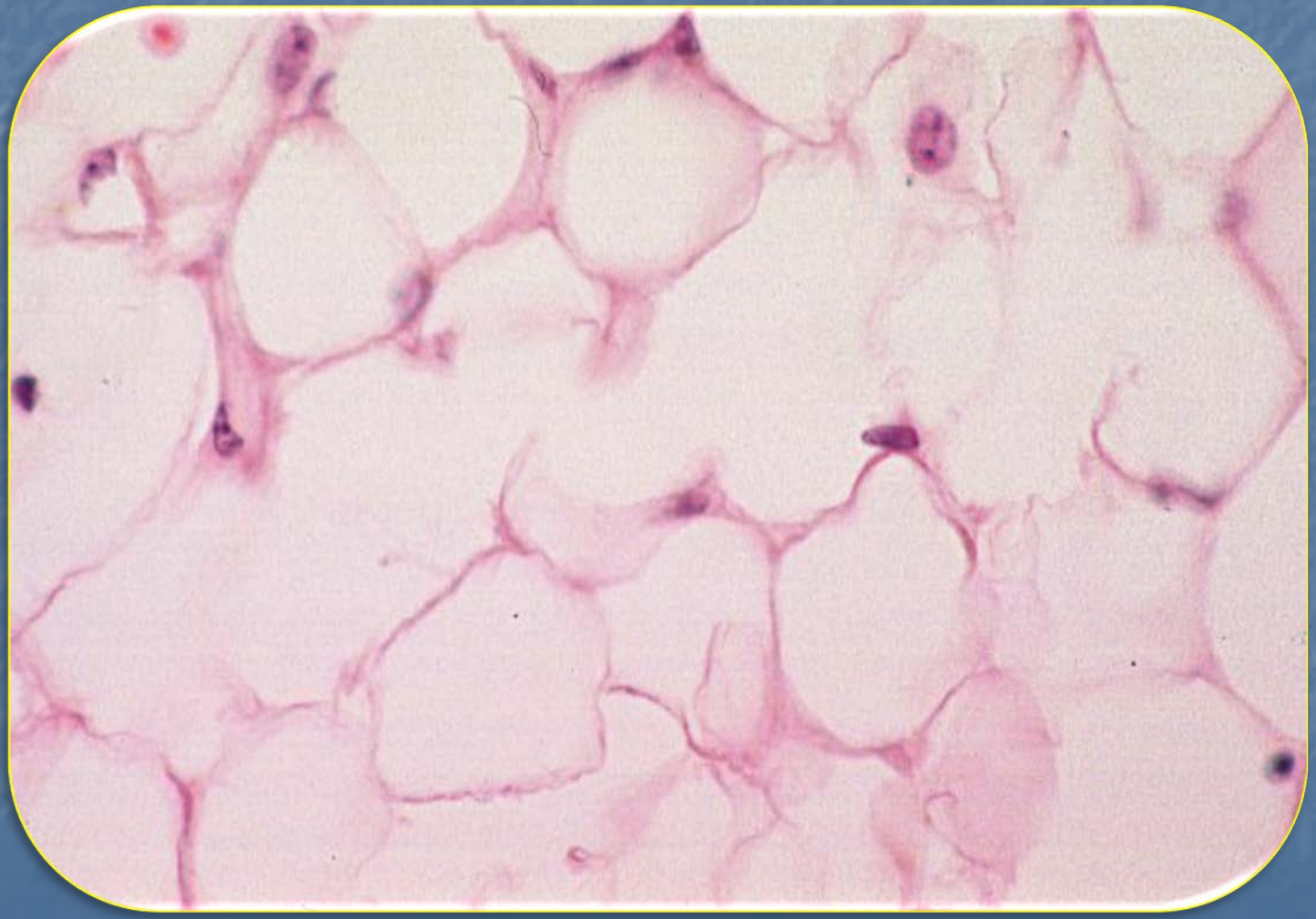

Two types of fat cell

- White fat cell
- Most common
- Unilocular - single, large lipid droplet
- Large diameter (>100u)

- Subcutaneous
- Omentum
- Mesentery

- Brown fat cell
- Less common
- Multilocular – many small droplets
- Common in new-born

- Around kidney
- Neck
- Mediastinum

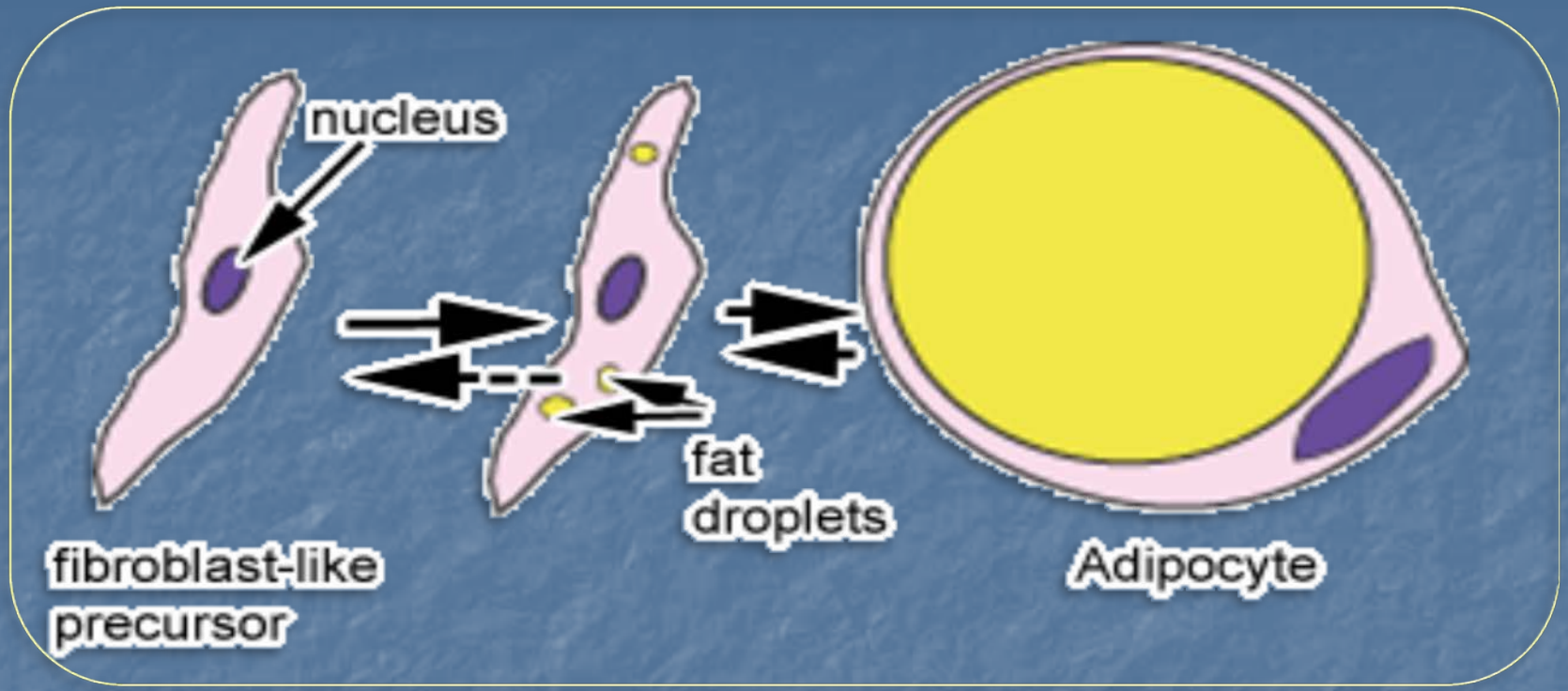

- Fat cells are thought to develop from fibroblast-like cells
- Fat droplets coalesce into a large droplet, leaving only a thin rim of cytoplasm
- Nucleus is usually pushed to the side

Fat cells

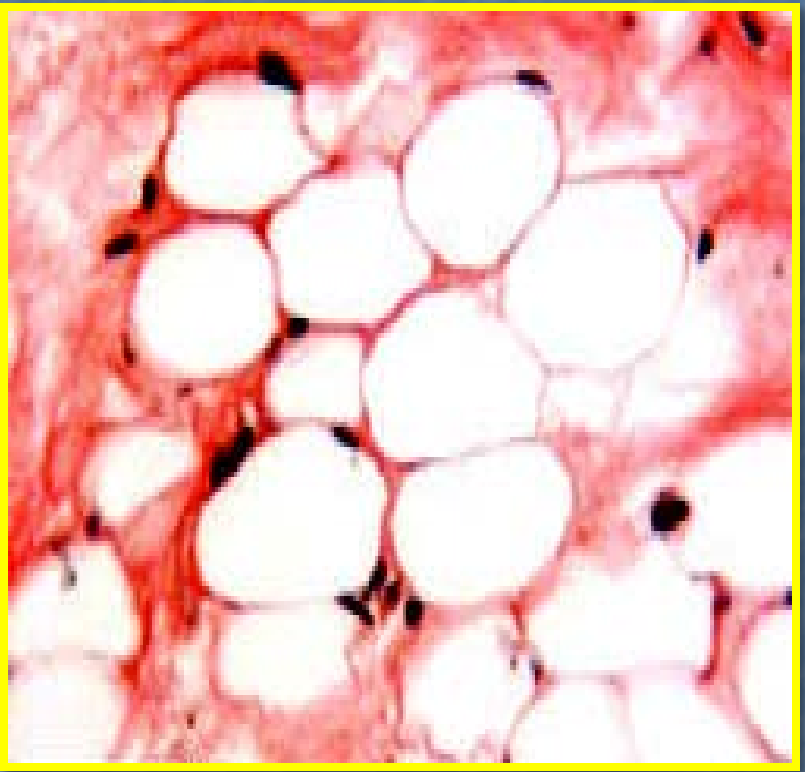

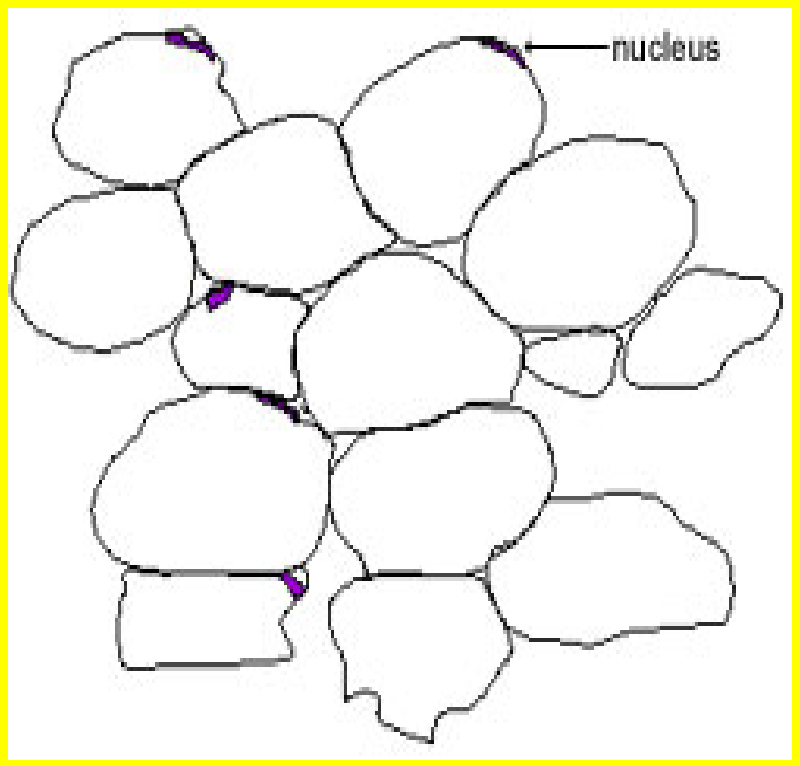

When tissue is fixed and stained, the single large lipid droplet is extracted and the cells look empty

Identification of lipids

1. Solubility - differentiation of lipids by their solubility in various solvents
2. Examination by polarised light
3. Reduction of osmium tetroxide
4. Demonstration by fat soluble dyes
5. Histochemical methods

1. Solubility

- Keilig's extraction using fresh human brain, extracted with 3 changes over 24 hours
- Cold acetone – simple lipids, neutral lipids & cholesterol
- Hot acetone – compound lipids such as cerebrosides
- Hot ether – phosphatides such as lecithin and cephalin
- Hot chloroform and methanol – all lipids
- Following extraction, blocks hydrated through alcohol to water, frozens cut and stained with Sudan black

2. Examination by polarised light

- Three types of refractility:

- Isotropic (monofringent) – neutral fats & fatty acids
- Anisotropic (birefringent) – any crystalline lipid
- Maltese cross (birefringent) – cholesterol esters
- Also use phase contrast microscopy

Polariser and phase contrast

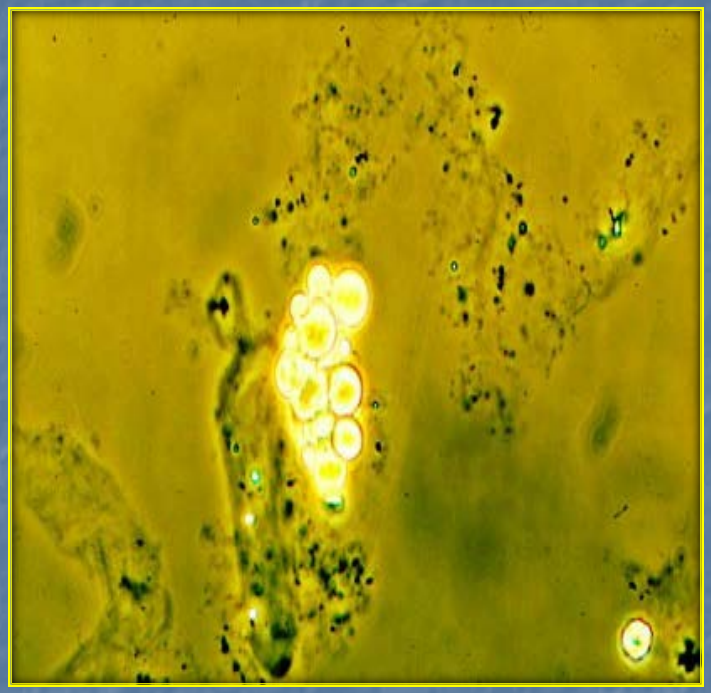

3. Reduction of osmium tetroxide

- Colourless OsO_4 to black OsO_2
- Marchi's for degenerate myelin
- After normal myelin has been oxidised by chrome salts, it will not react with osmium tetroxide
- Degenerate myelin contains oleic acid which is not oxidised by chrome salts and will reduce osmium tetroxide to black osmium dioxide

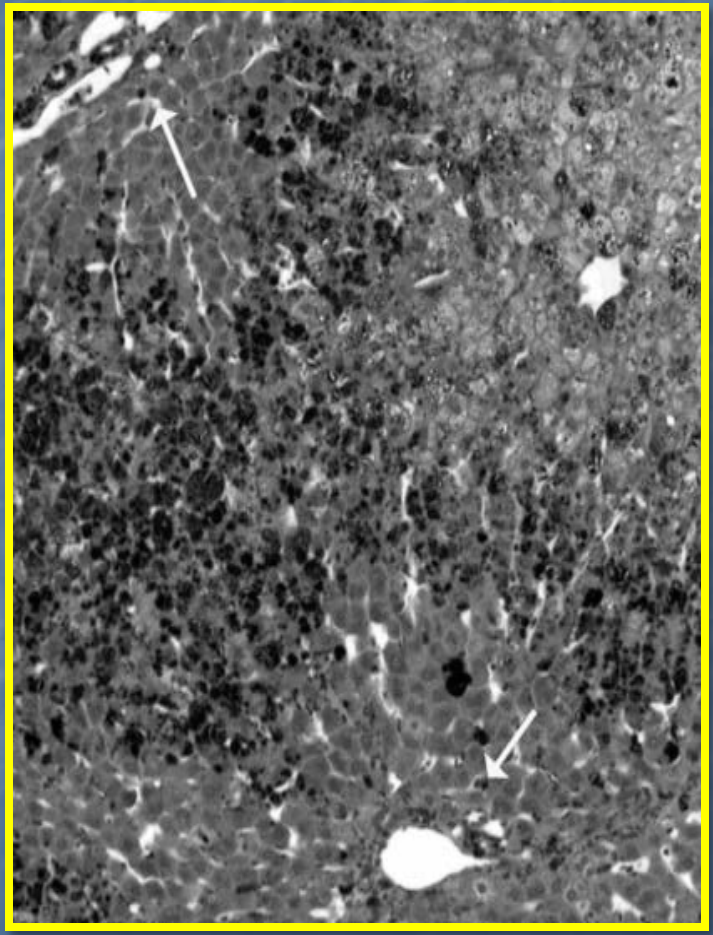

4. Fat soluble dyes

- These dyes have a high affinity for fats, lipids, lipoproteins and triglycerides
- The fat soluble dyes are oil red O, Sudan II, Sudan III, Sudan IV and Sudan black B
- Staining solutions are generally alcoholic

Oil red O

- Demonstrates neutral lipids and fatty acids
- Oil red O is a fat-soluble dye
- More soluble in fat than in the dye solvent
- Solvent is usually isopropanol
- Cut frozen sections, usually leave unfixed
- Stain in oil red O and counterstain
- Mount in aqueous media

Oil red O

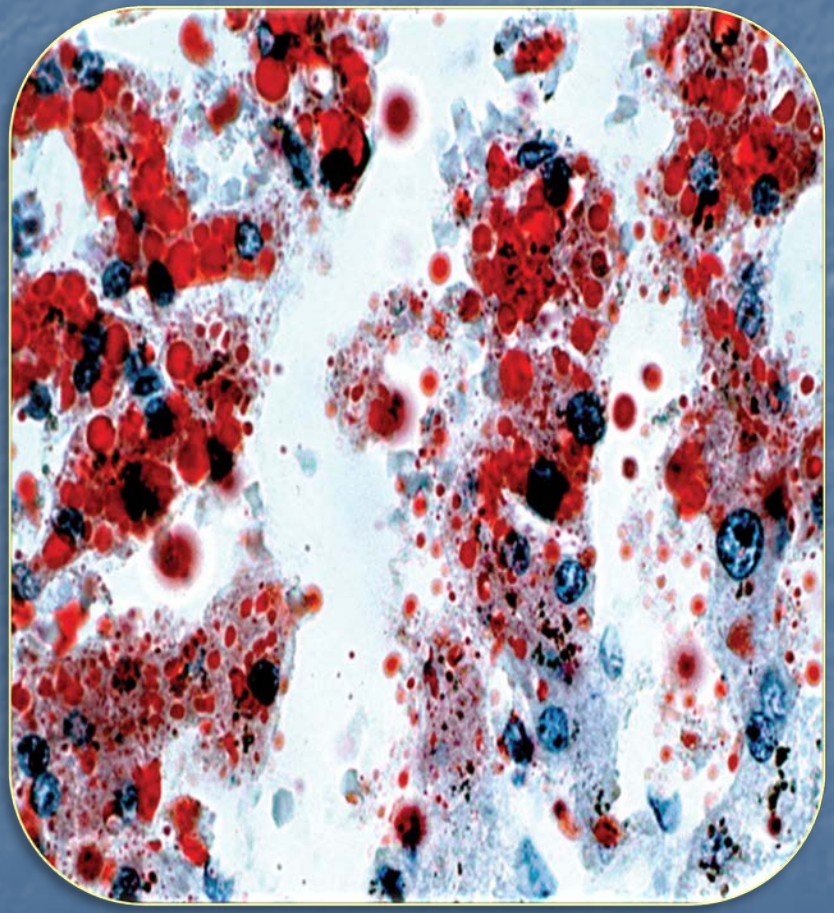

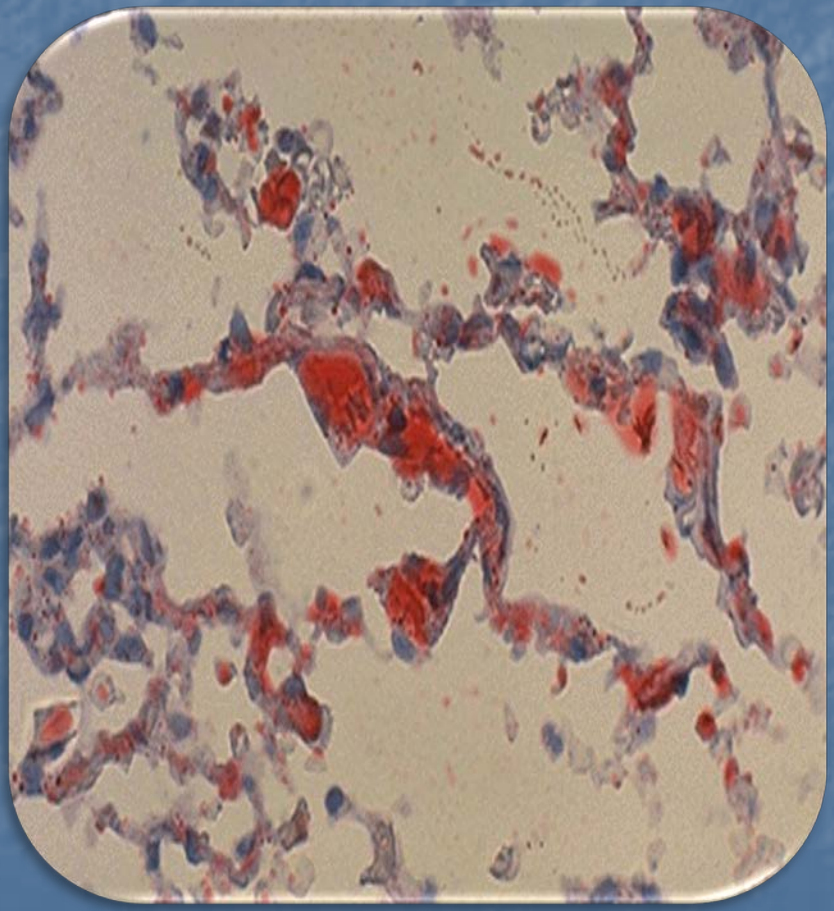

Sudan IV and Sudan black B

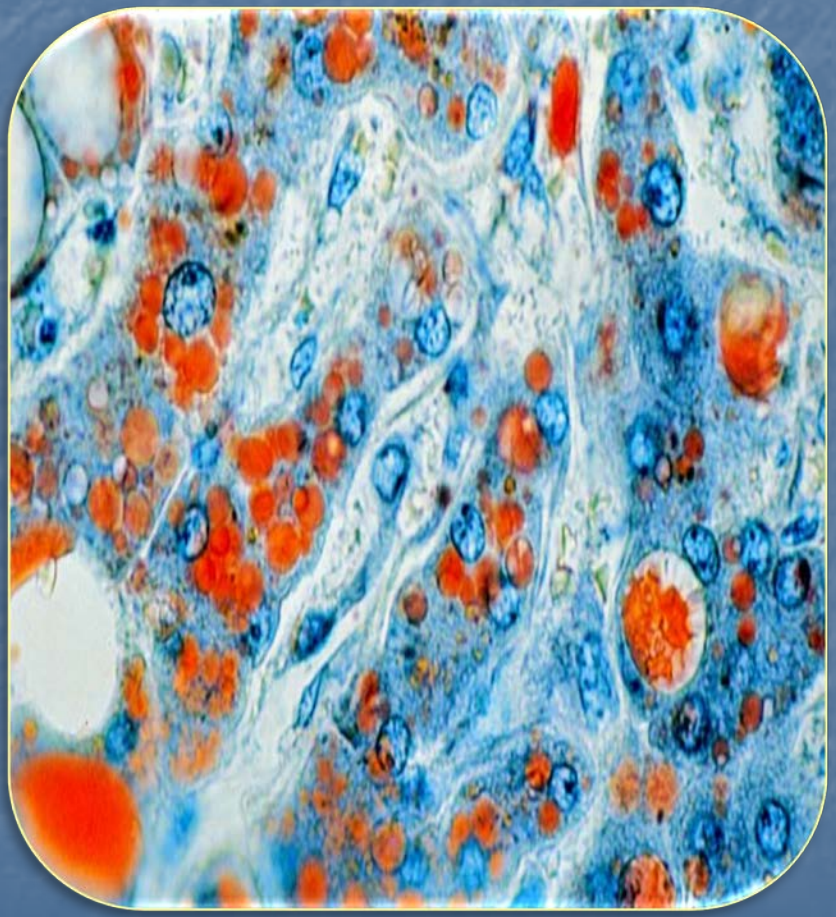

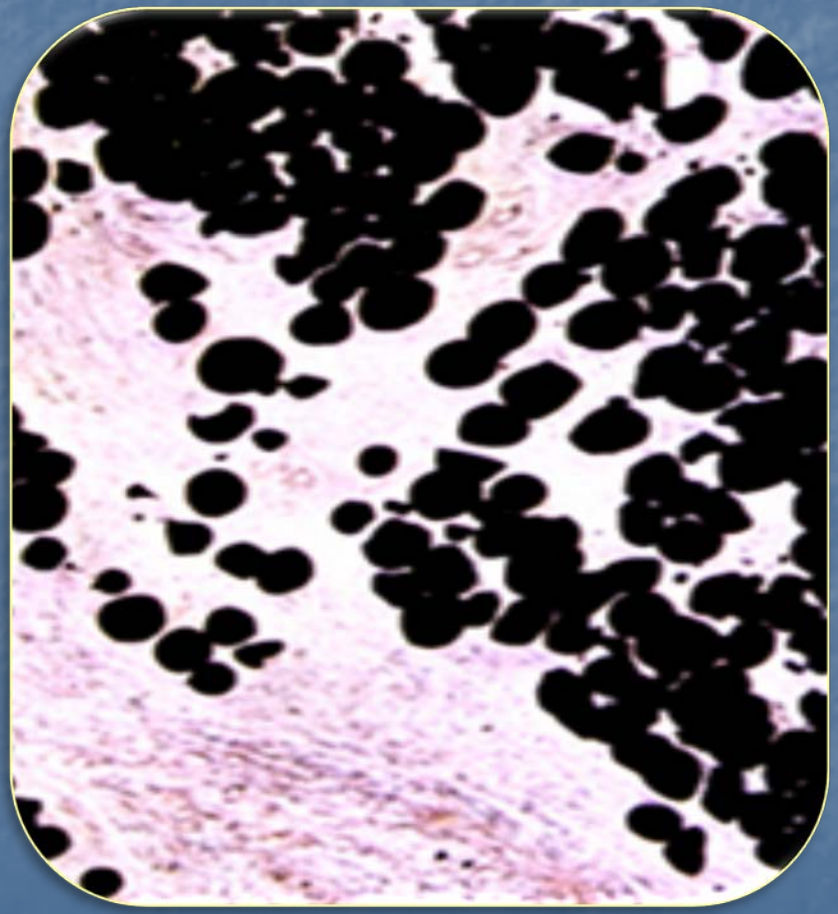

Bromine - Sudan black B

- One section stained with Sudan black after bromination
- Control section stained without bromination
- Cholesterol, cholesterol esters and phospholipids stain blue / black but remain unstained in control

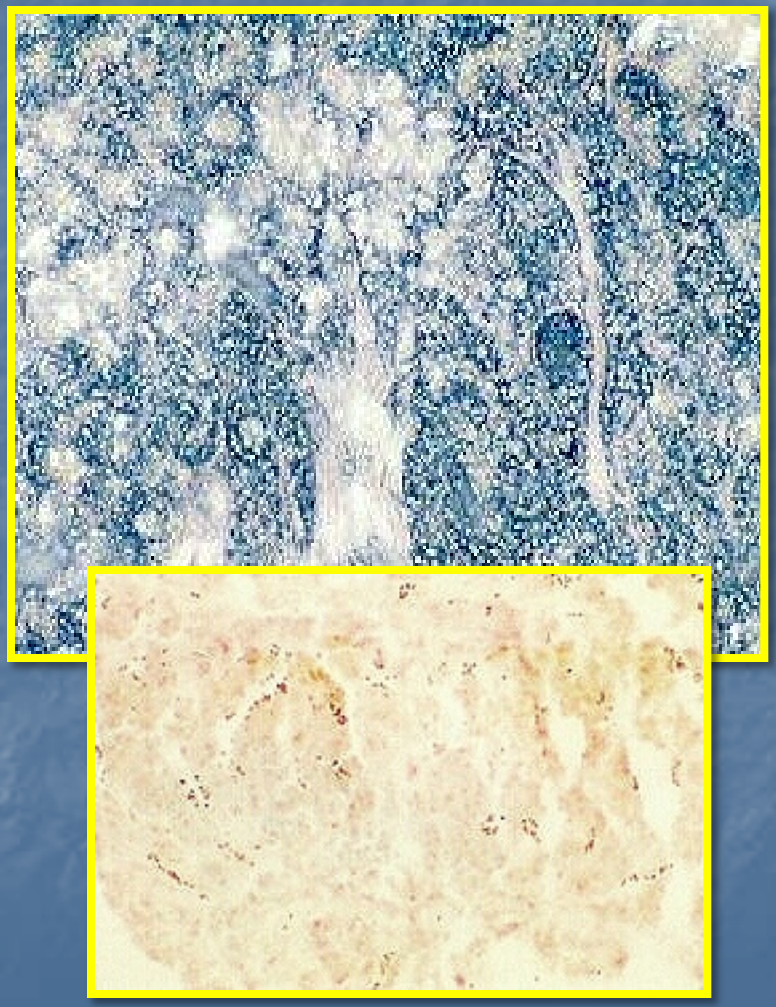

5. Histochemical methods

Nile blue sulphate

- Demonstrates acidic and neutral fats
- Nile blue sulphate contains 2 components
- Red oxazone which dissolves in neutral fats
- Blue oxazine reacts with fatty acids & phospholipids
- Fix frozen sections in formol calcium for 1 hour
- Method requires 2 solutions:
  - Nile blue sulphate at 60°C for 30 minutes
  - Methyl green solution for 5 minutes

Nile blue sulphate

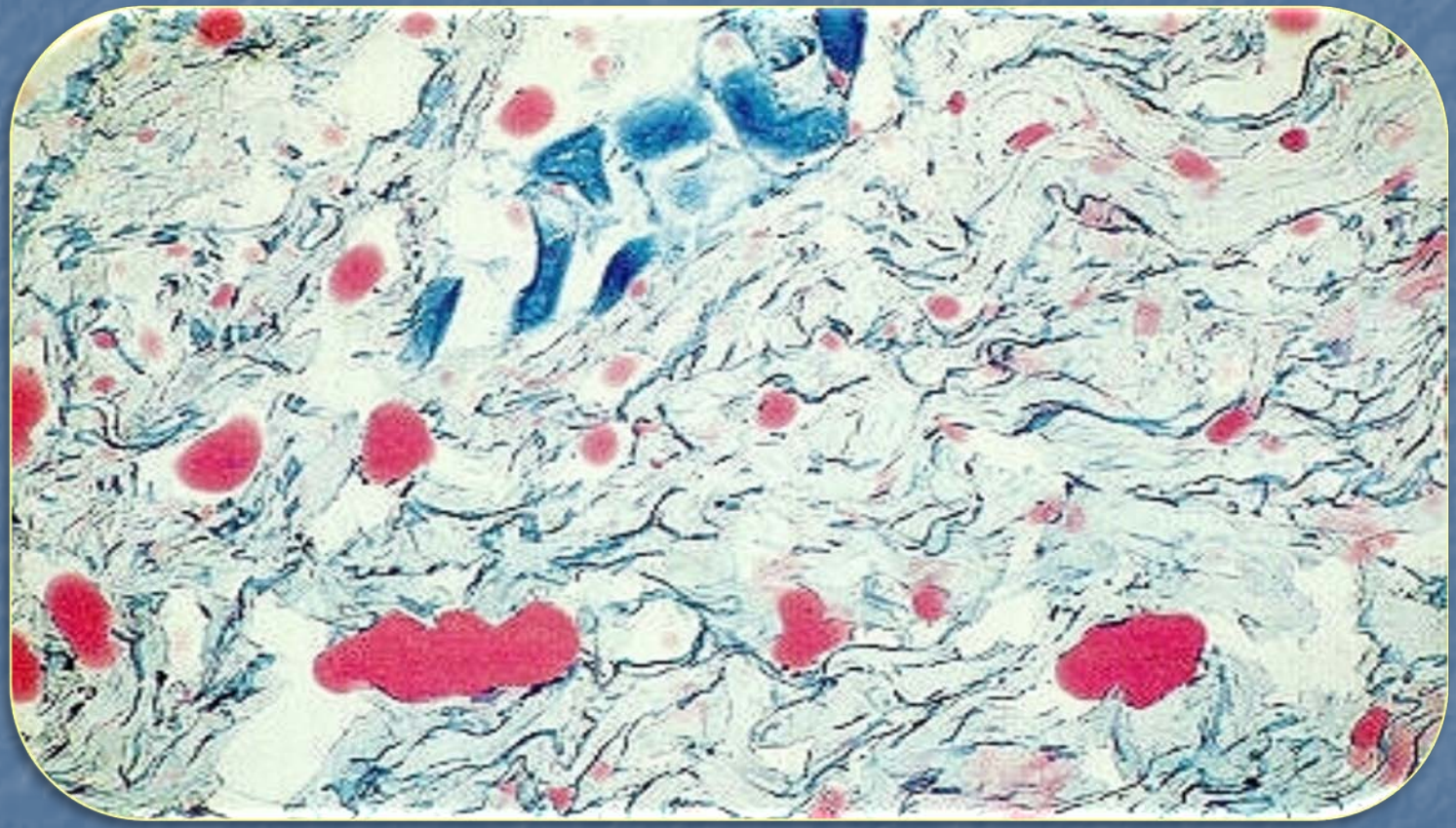

Neutral fats, oils and cholesterol esters – red
Fatty acids and phospholipids - blue

Perchloric acid-naphthaquinone (PAN)

- Cholesterol and cholesterol esters stain grey/blue

Other histochemical methods

- Luxol fast blue – phospholipids (and myelin)
- Baker's acid haematein – phospholipids
- Fischler's method – fatty acids
- Osmium tetroxide - a naphthylamine (OTAN) – phospholipids – useful for differentiating hydrophilic lipids (sphingomyelin, cerebrosides etc) from hydrophobic lipids (fatty acids & cholesterol esters)
- Fluorescent dyes such as phosphine 3R and benzpyrene

Why demonstrate fat

- Fat may appear abnormally as a result of trauma such as bone fractures
- Fat released into bloodstream can cause emboli
- Identify fatty tumours such as liposarcoma
- Identify fat in other pathological conditions

Lipid pathology

1. Fatty degeneration
2. Lipoma
3. Liposarcoma
4. Atheroma
5. Thecoma
6. Tay-Sach's disease

1. Fatty degeneration

- Also known as steatosis or fatty change
- Abnormal retention of lipid within cells

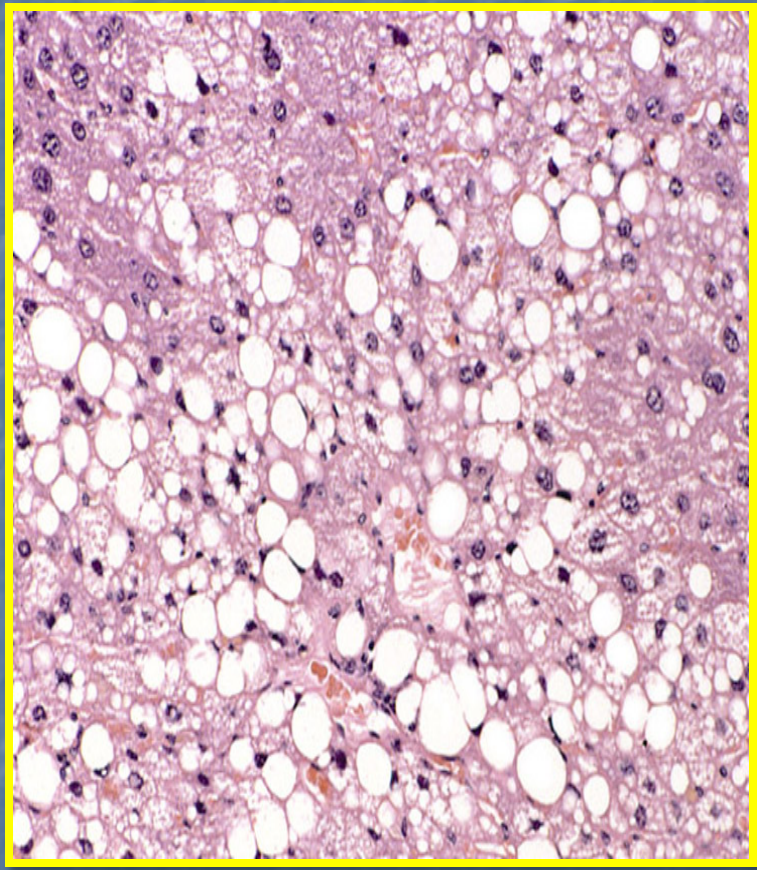

2. Lipoma

- Benign tumour composed of adipose tissue (body fat)
- Most common benign soft tissue tumour
- Usually moveable and painless

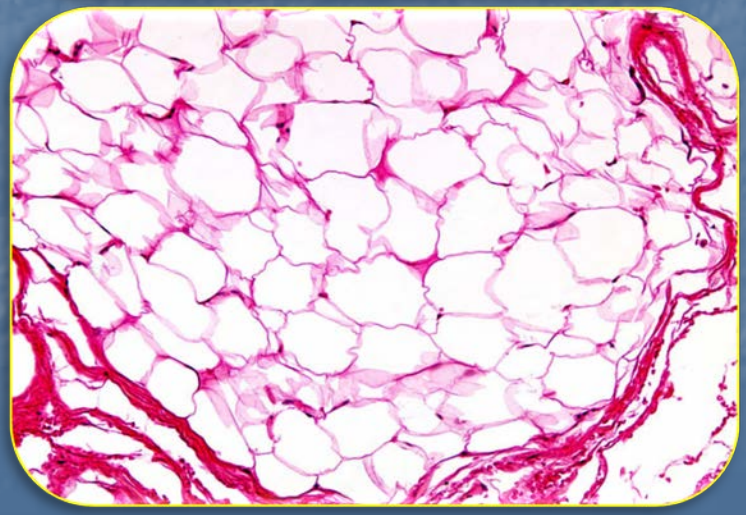

3. Liposarcoma

- Rare, malignant tumour arising in fat cells deep in soft tissue such as the thigh
- Large and bulky often with satellites outside of the main tumour

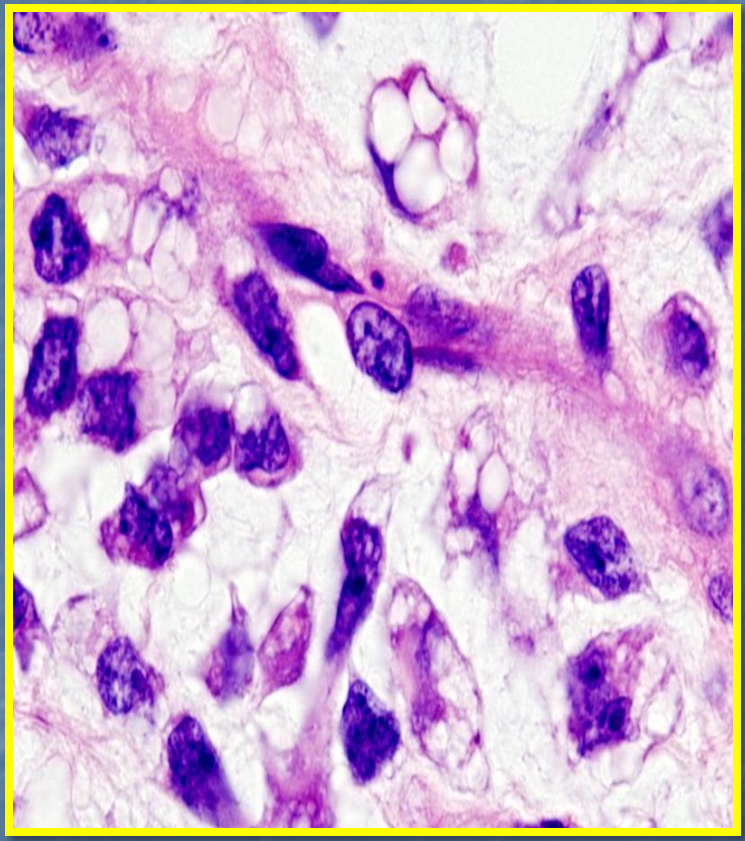

3. Liposarcoma

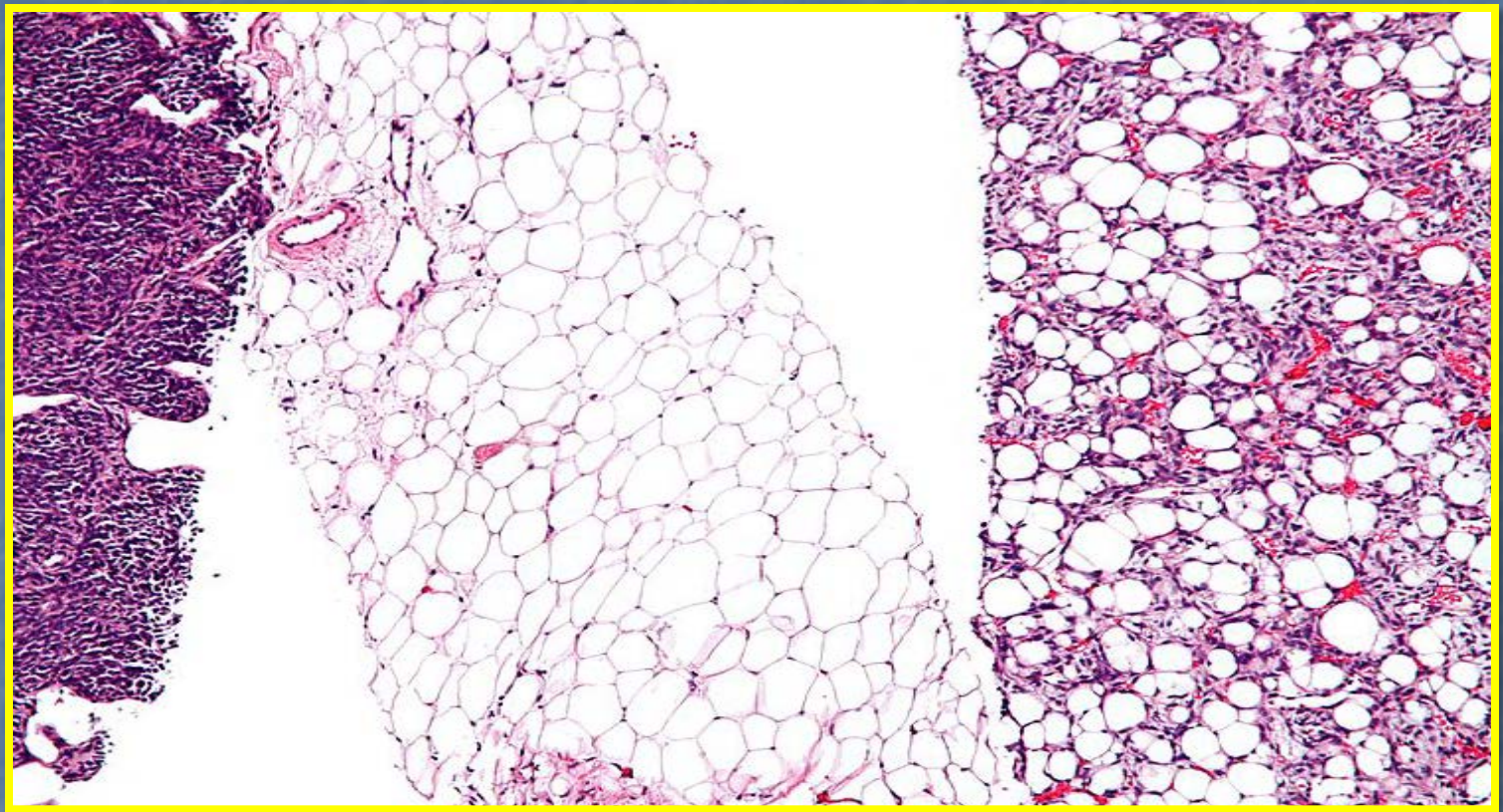

- Undifferentiated liposarcoma left side
- Differentiated liposarcoma on right side
- Benign fatty tissue in the centre (has fewer blood vessels)

4. Atheroma

- Swelling in arterial walls with macrophages that contain fatty acids and cholesterol (clefts)
- Also contain calcium and fibrous connective tissue
- Occurs in atherosclerosis

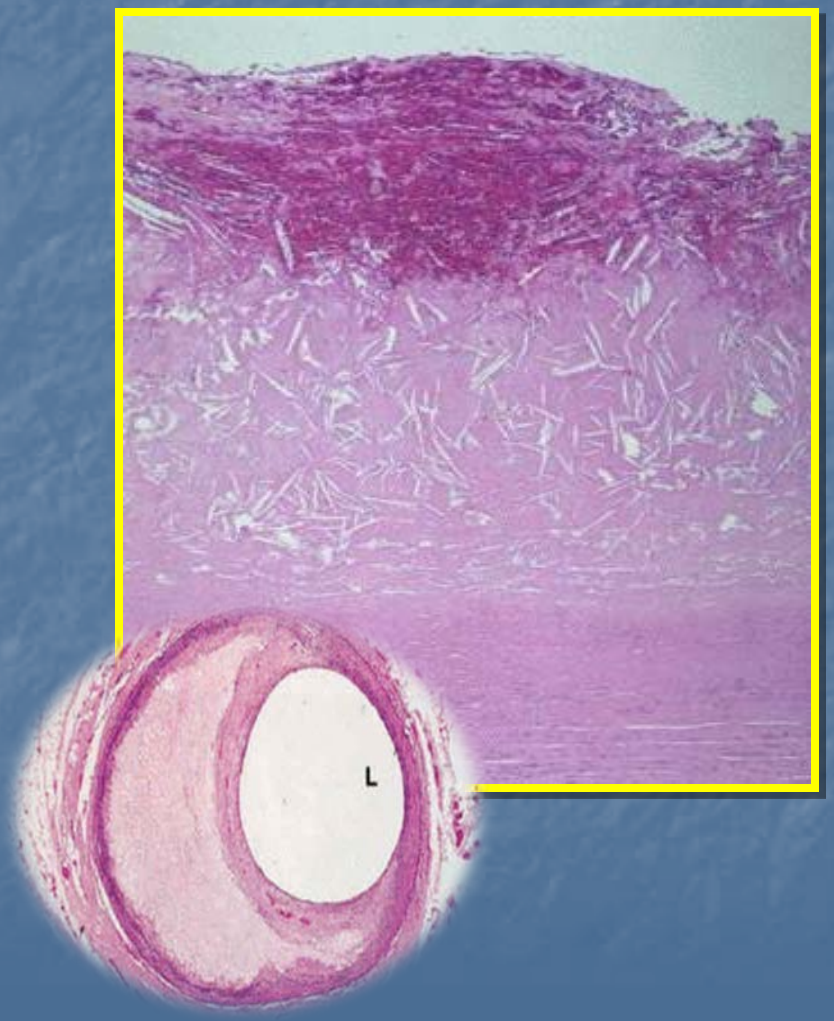

5. Thecoma

- Benign ovarian tumour composed of theca cells
- Oestrogen producing
- Occurs in older women, generally after the menopause
- Tumour cells have abundant lipid-filled cytoplasm

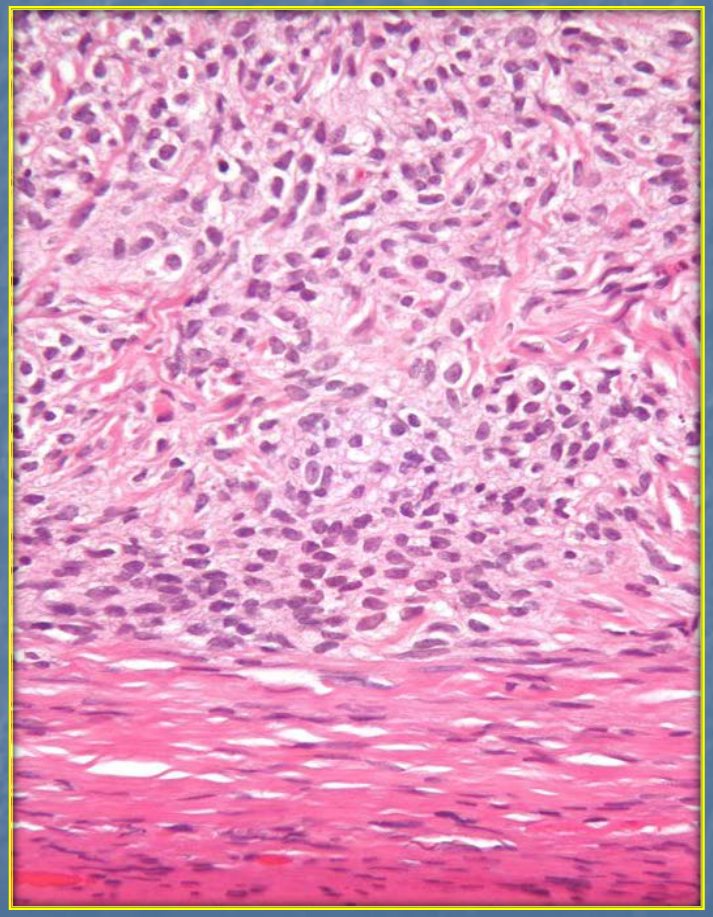

6. Tay Sach's disease

- Known as gangliosidosis or hexosaminidase A deficiency
- Caused by gangliosides accumulating in nerve cells
- Progressive mental deterioration in children with death usually by 4 years
- Lipid stored as concentric, laminated bodies