

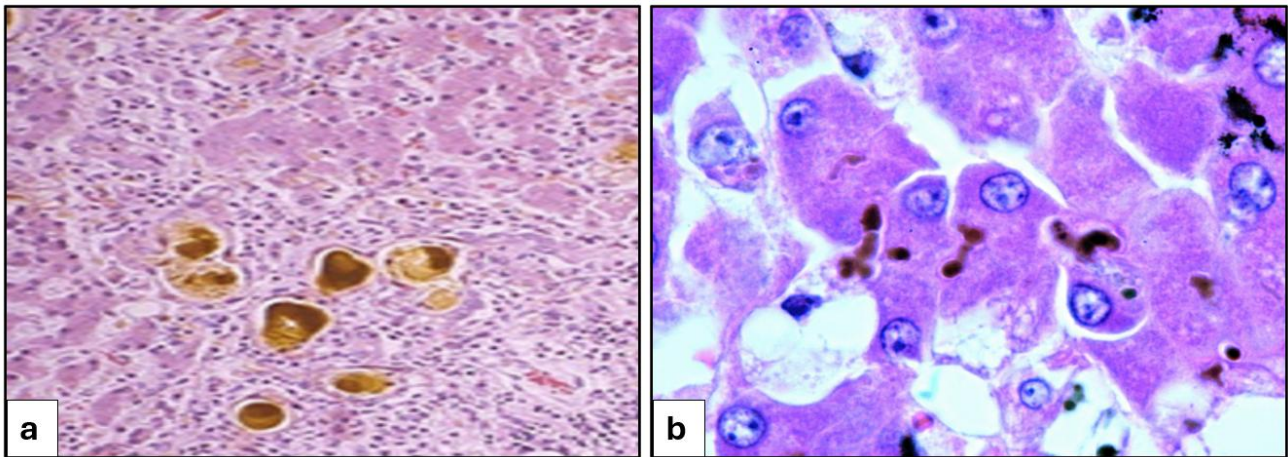
# Z is for Zenker's fluid

**A-Z of Staining** - a series of articles where we share a little extra information about stains, staining techniques and some of the interesting chemicals associated.



**Welcome to the ABC of Staining where we continue with the letter 'Z' for Zenker's fluid.**

Zenker's fluid is a specialist fixative used in histology to preserve tissue samples for microscopic examination. It provides excellent fixation for nuclear chromatin, cytoplasmic and connective tissue features and is often recommended for haematopoietic tissues such as lymph nodes, spleen, thymus and bone marrow. The fixative works by cross-linking and coagulating proteins, which stabilizes the tissue structure and preserves cellular detail for microscopic examination. The fixative penetrates tissues relatively slowly with a recommended maximum tissue thickness of about 5 mm and a typical fixation time of between ten and twenty-four hours. The stock solution consists of a mixture of mercuric chloride ( $\text{HgCl}_2$ ), potassium dichromate ( $\text{K}_2\text{Cr}_2\text{O}_7$ ), sodium sulphate ( $\text{Na}_2\text{SO}_4$ ) and water. Although the working solution requires glacial acetic acid to be added prior to use, both the stock and working solutions are stable for many years. If the glacial acetic acid is replaced with formaldehyde, the resulting solution becomes known as Helly's fixative (or formol-Zenker) and is preferable for the traditional staining of mitochondria. However, this solution is only stable for a few hours since the formaldehyde and dichromate react to produce formic acid and chromium, causing the colour of the solution to change from orange to green.



**Figure 1. Chrome pigment (a) and black deposits of mercury (b) in tissue sections**

Following fixation in Zenker's fluid, tissues must be thoroughly washed in running water to remove excess dichromate to prevent the formation of chrome pigment during tissue processing (Figure 1a). Though the fixative is compatible with many staining methods such as phosphotungstic acid haematoxylin (PTAH) and trichrome stains, there is a critical requirement for paraffin sections to be treated beforehand to remove the black mercury pigment from appearing in stained sections (Figure 1b). The term 'dezenkerize' is commonly applied to this procedure which treats tissue sections with an iodine and sodium thiosulphate (hypo) sequence prior to routine staining. Since the fixative contains toxic components of mercuric and dichromate salts, careful handling and disposal of the solution is essential. Although this can be partly overcome by replacing the mercury component with a safer alternative such as zinc chloride, this fixative does not offer the same quality of success as the original fluid.

### **Further reading**

Ajileye A & Esan E. (2022). Fixation and fixatives in histopathology: a review. *Bayero Journal of Pure and Applied Sciences* 2022;15(1):231-243. doi: [10.4314/bajopas.v15i1.32](https://doi.org/10.4314/bajopas.v15i1.32)

Dağdeviren et al (2024). Histological fixation process and fixatives. *International Turkish Journal of Agriculture - Food Science and Technology (TURJAF)* 2024;12(8). doi: [10.24925/turjaf.v12i8.1482-1486.6808](https://doi.org/10.24925/turjaf.v12i8.1482-1486.6808)

**Dr Phil Bryant**

**February 2025**